



**Università degli studi di
Bari**
**Corso di Laurea in
Scienze Fisioterapiche
e nella
Professione Sanitaria in Infermiere**
Facoltà di Medicina e Chirurgia

**CORSO DI
ANATOMIA UMANA**

Anatomia Umana

- Anatomia Macro- e Microscopica.
 - **Apparato circolatorio**
 - **Apparato emolinfopoietico**
 - **Apparato respiratorio**
 - **Apparato urinario**
 - **Apparato digerente**
 - **Apparato endocrino**
 - **Apparato locomotore**
 - **Apparato nervoso**
 - **Apparato genitale maschile**
 - **Apparato genitale femminile**
 - **Apparato tegumentario**

Gonadi o Didimi o testicoli

Vie spermatiche

Tubuli retti e rete testis
Epididimi
Canali deferenti
(funicoli o cordoni spermatici)
Condotti eiaculatori
Uretra comune

Gh. annesse

Alle vie spermatiche

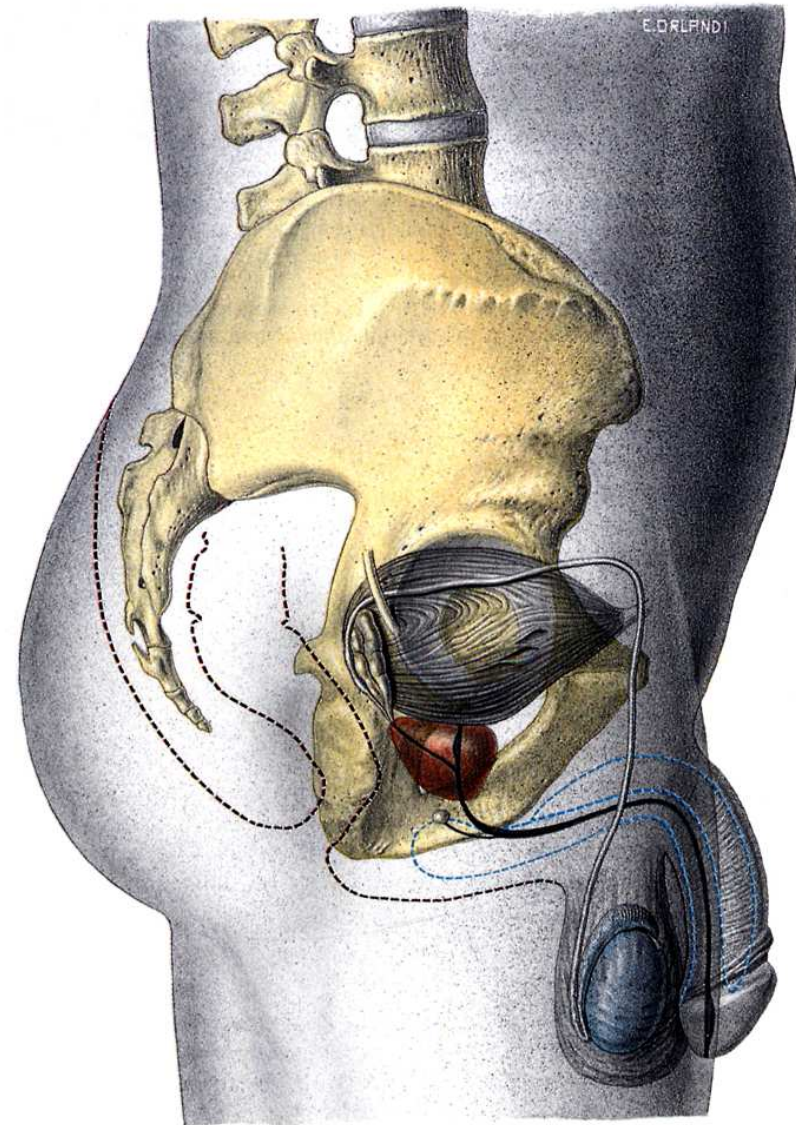
Vescichette seminali
Prostata
Gh, bulbouretrali

Genitali esterni

Pene
Borsa scrotale o scroto

Organi rudimentale

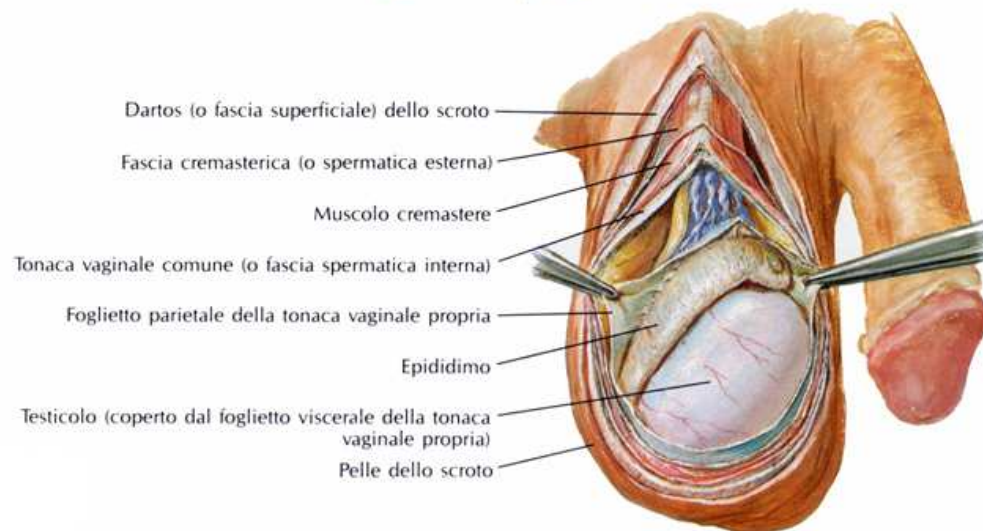
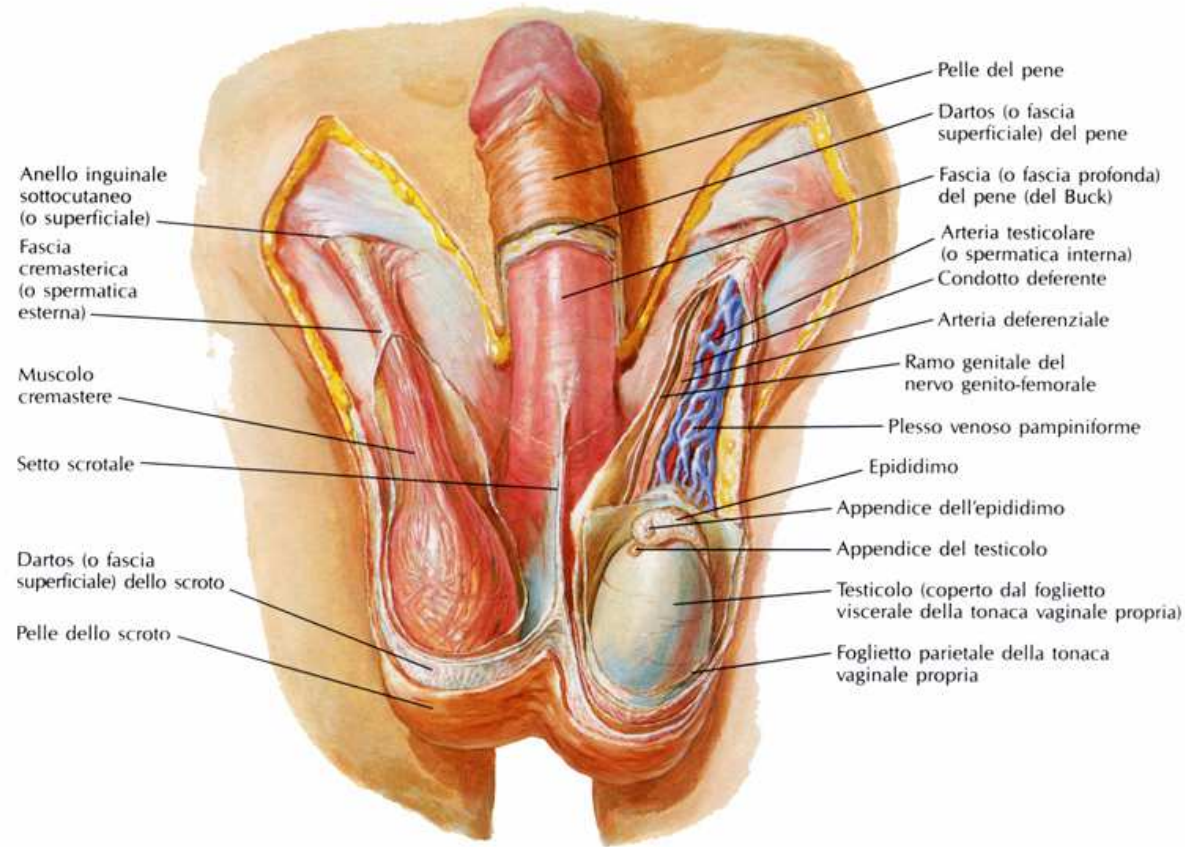
Appendice del testicolo
Appendice dell'epididimo
Paradidimo
Condotti aberranti



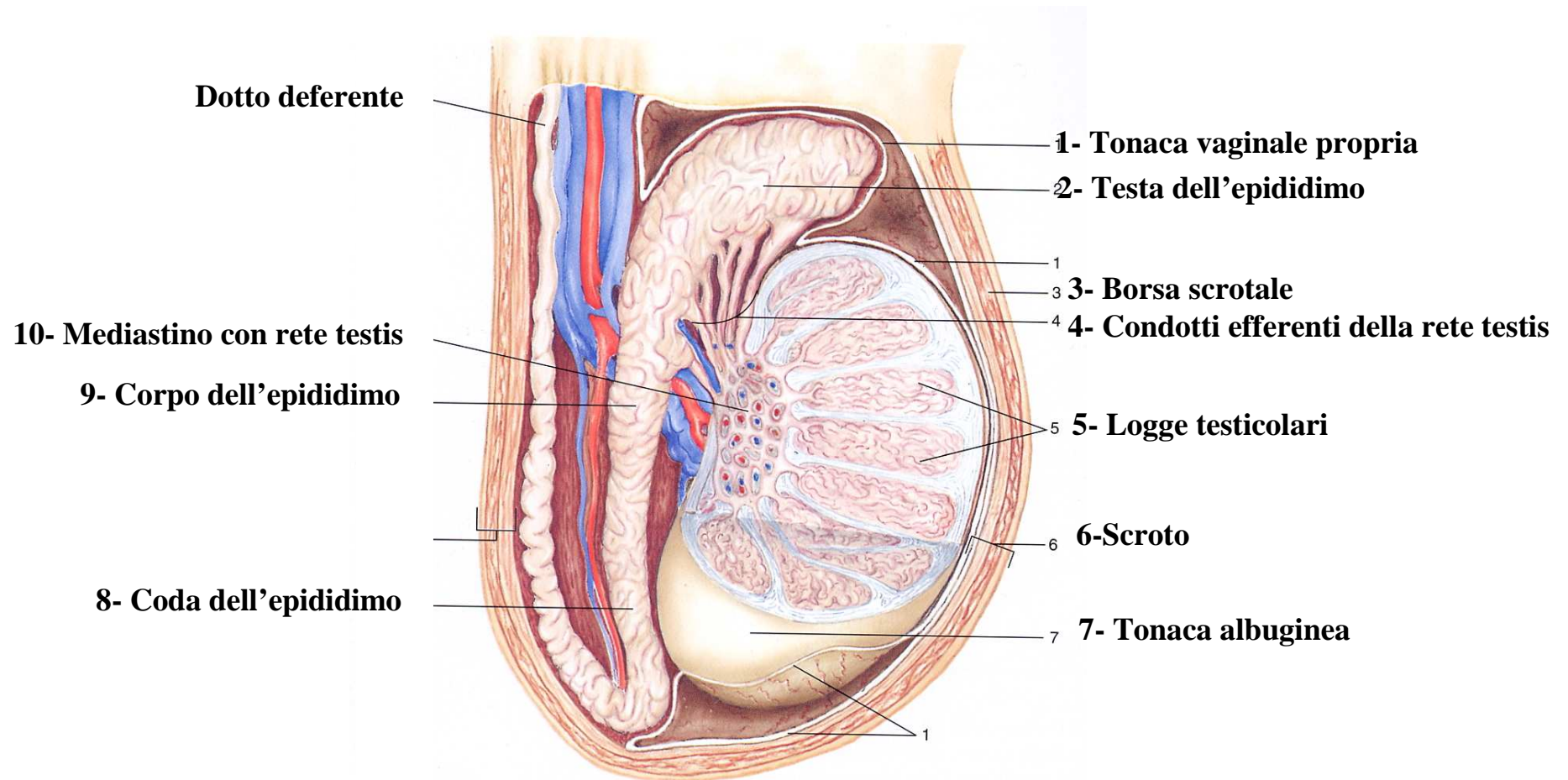
TESTICOLI O DIDIMI

Gonade maschile

- funzione gametogena
- funzione endocrina



STRUTTURA DEL TESTICOLO



STRUTTURA DEL TESTICOLO

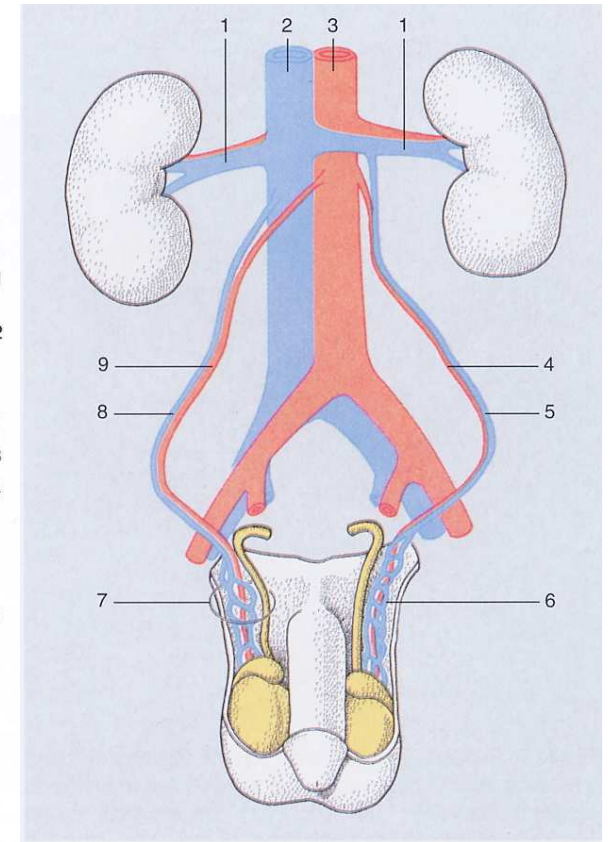
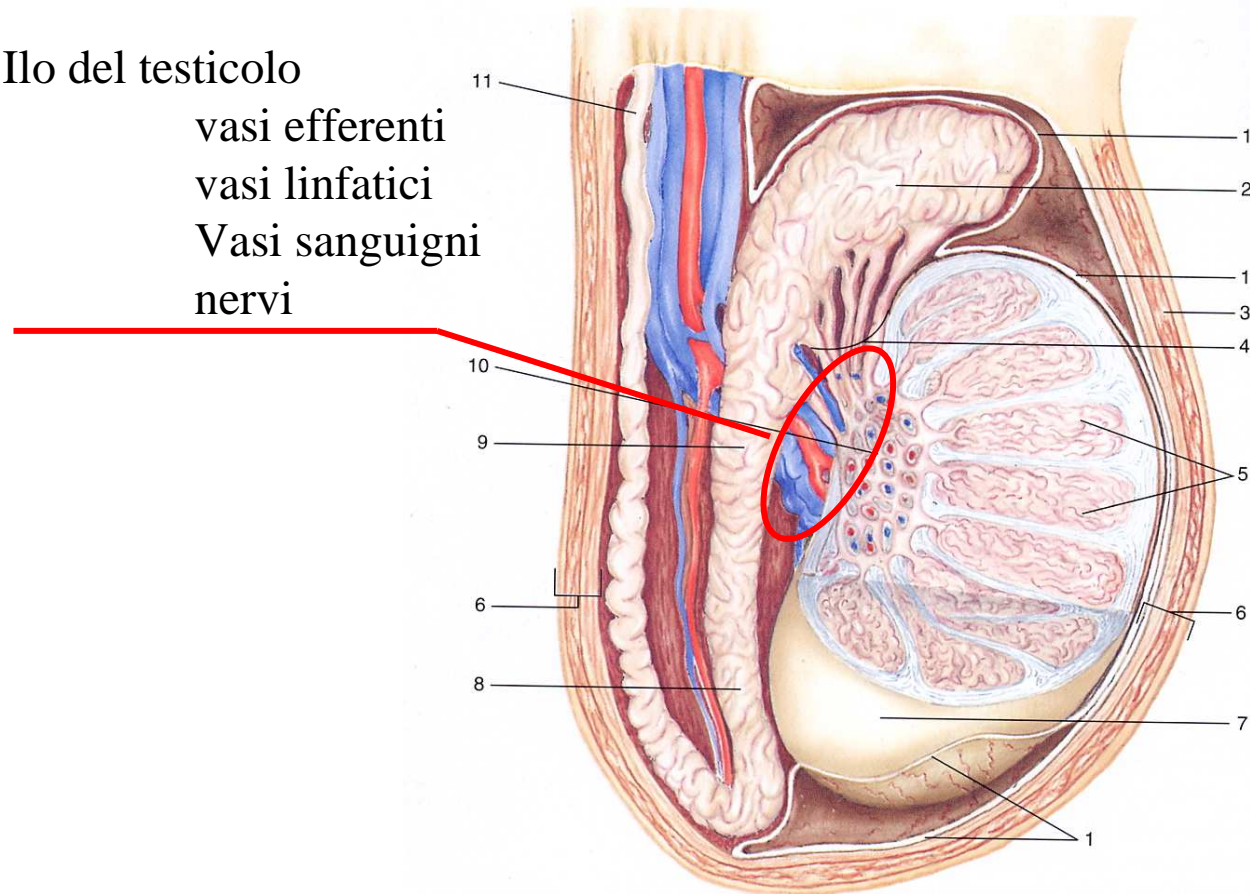
Ilo del testicolo

vasi efferenti

vasi linfatici

Vasi sanguigni

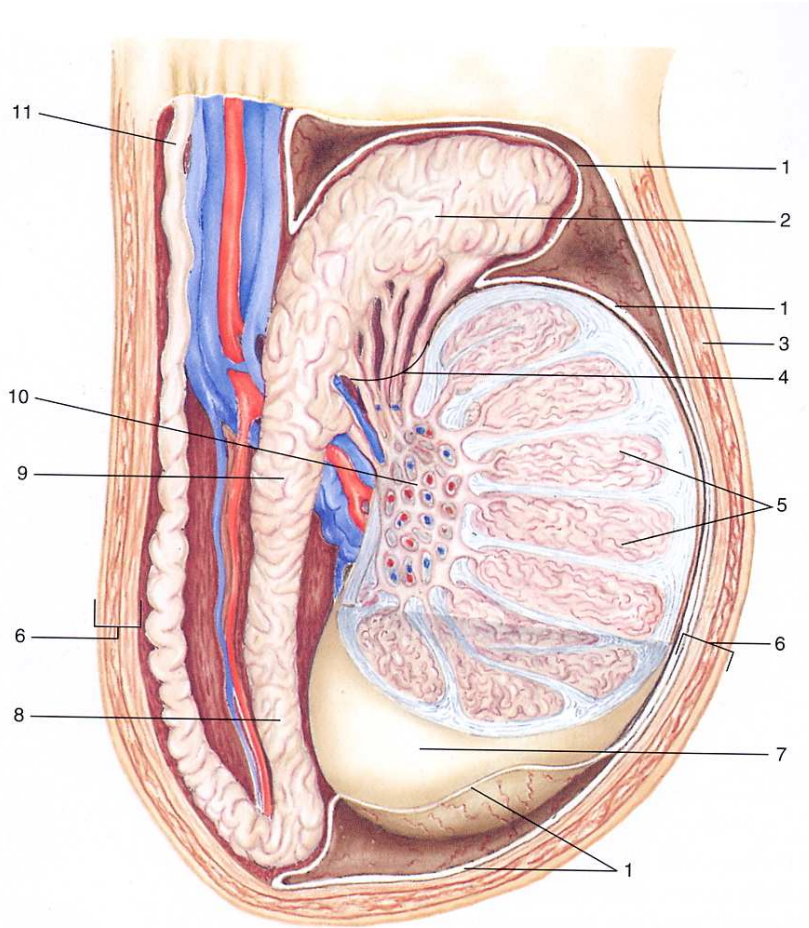
nervi



Vascularizzazione

- arteria testicolare
aorta addominale
- vena testicolare
- vasi linfatici

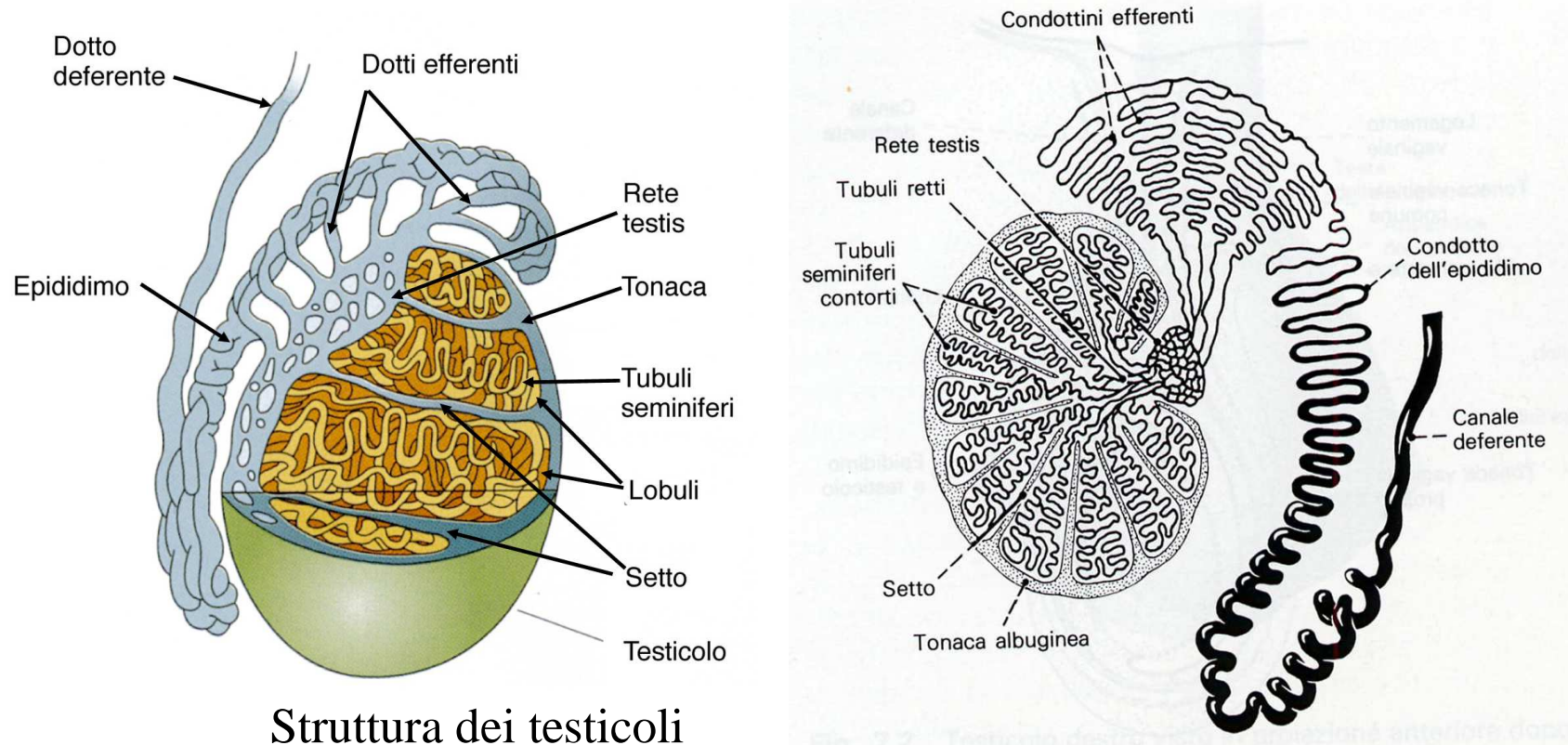
STRUTTURA DEL TESTICOLO



Tonaca vaginale propria

- epiorchio (f. viscerale)
- periorchio (f. parietale)
- mesorchio (regione posteriore)

cavità vaginale
idrocele



Struttura dei testicoli

Tonaca albuginea (scheletro fibroso)

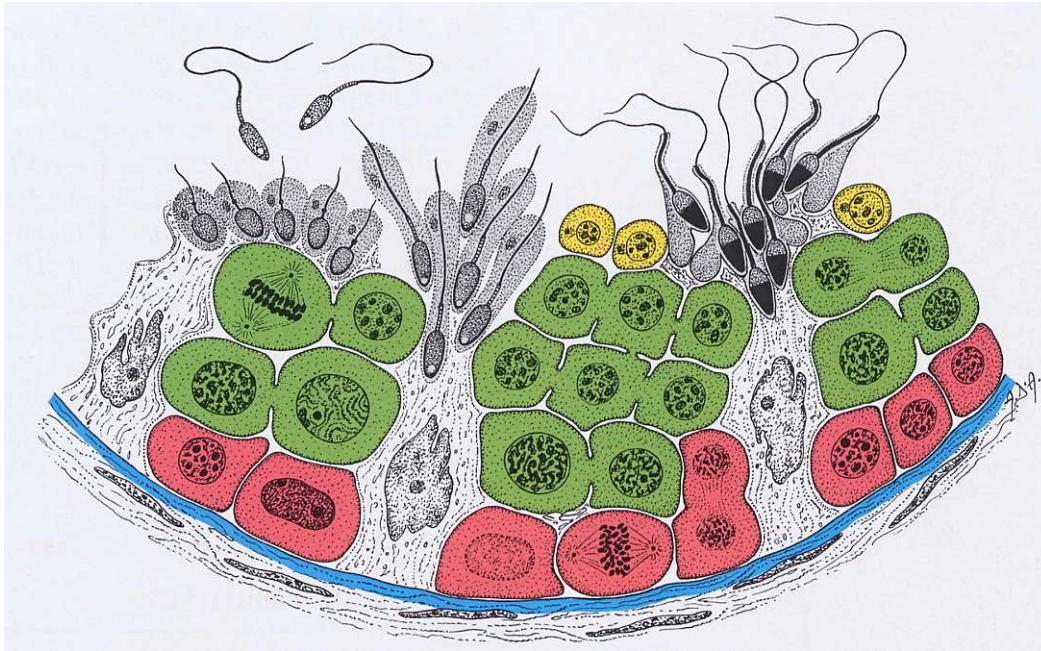
Tubuli seminiferi (parenchima)

Stroma

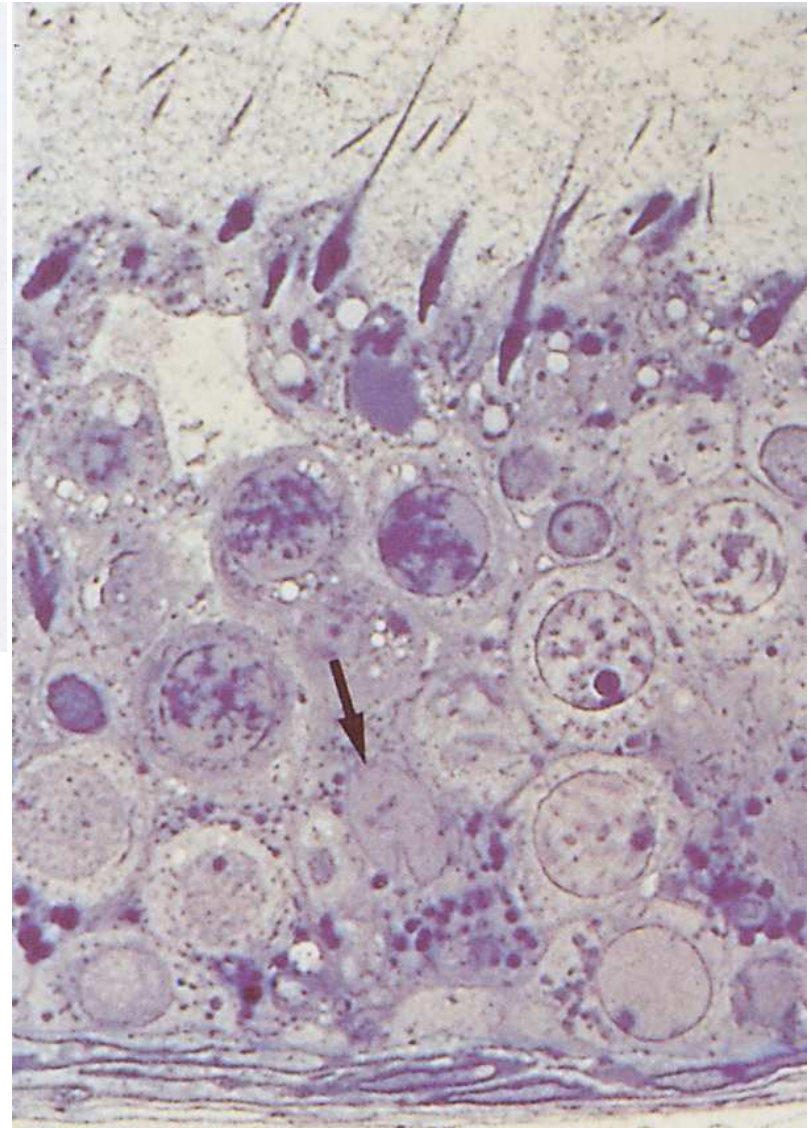
Cellelule endocrine di Leydig

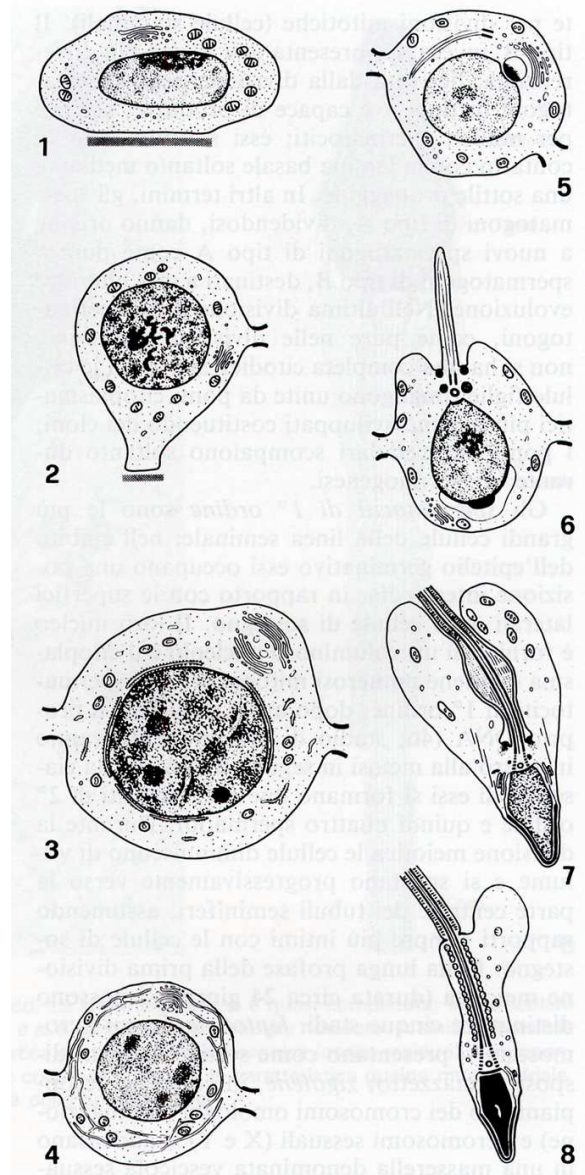
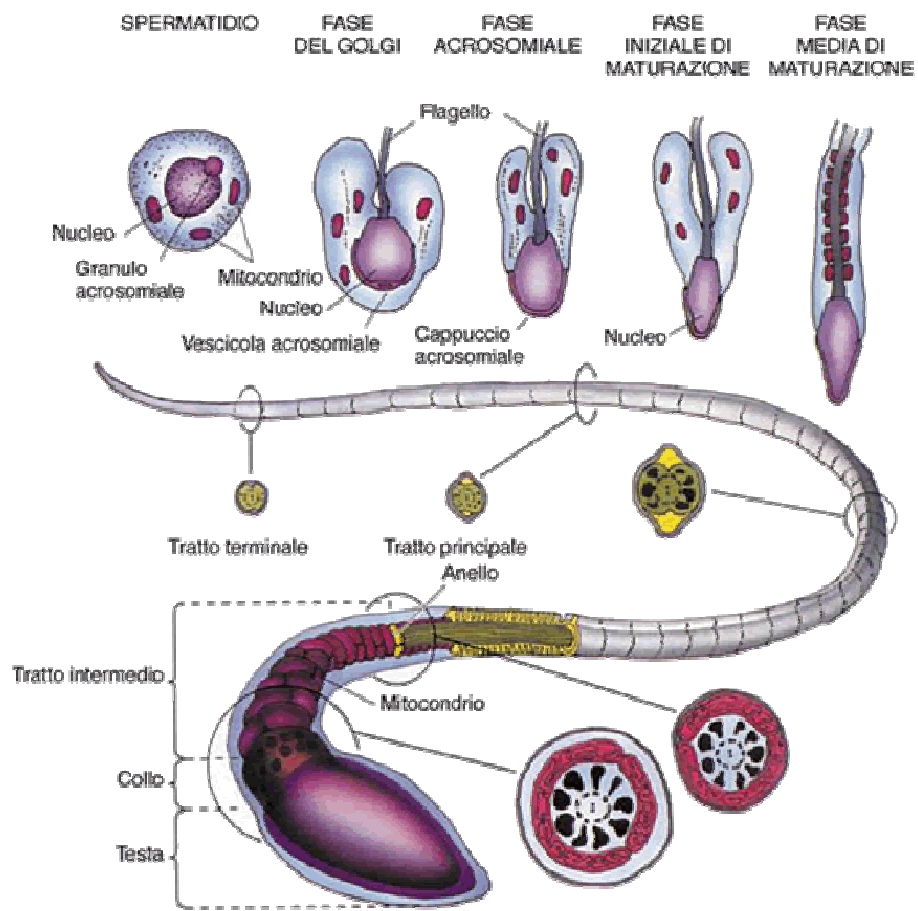
TESTOSTERONE

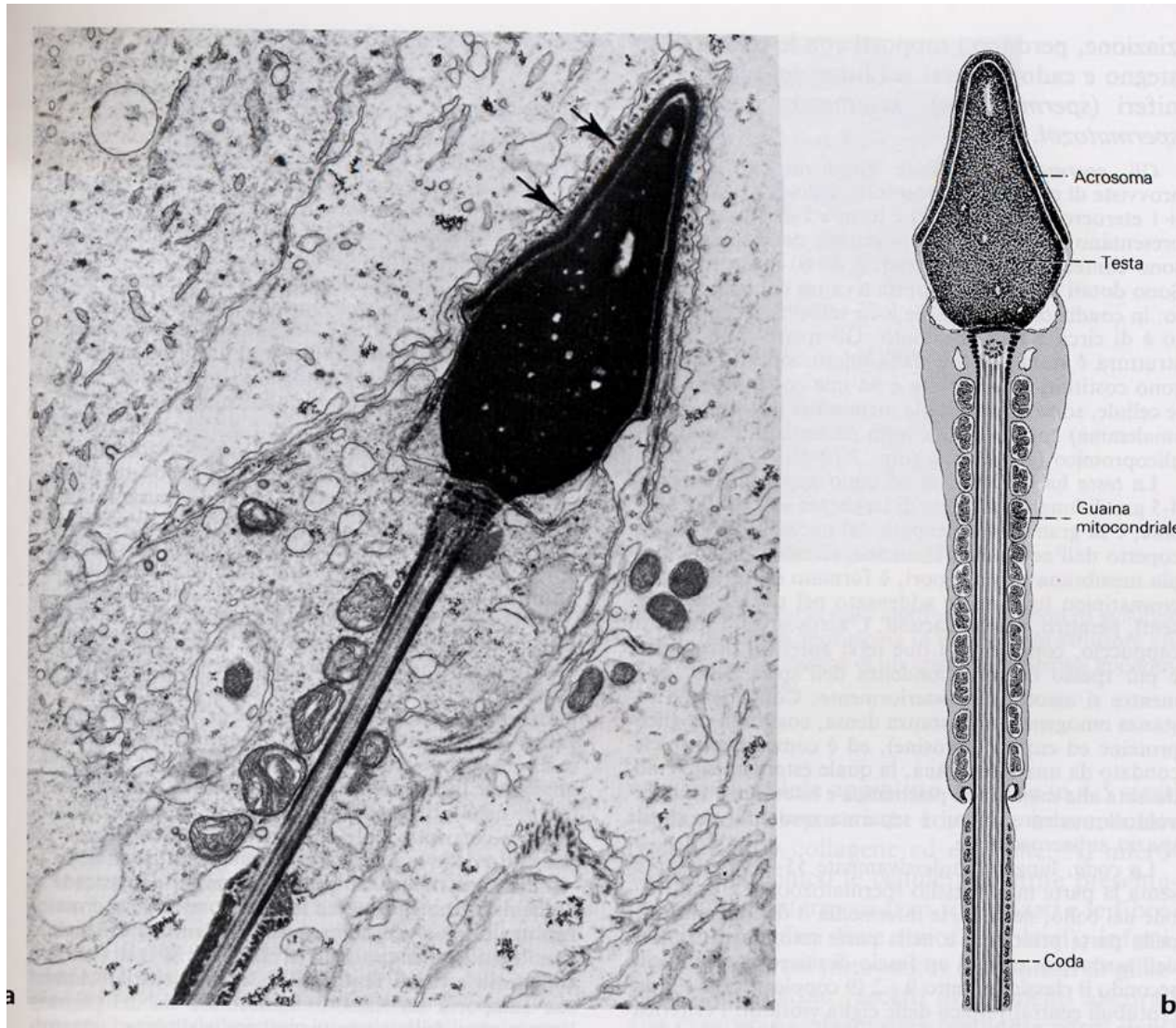
EPITELIO DEL TUBULO SEMINIFERO



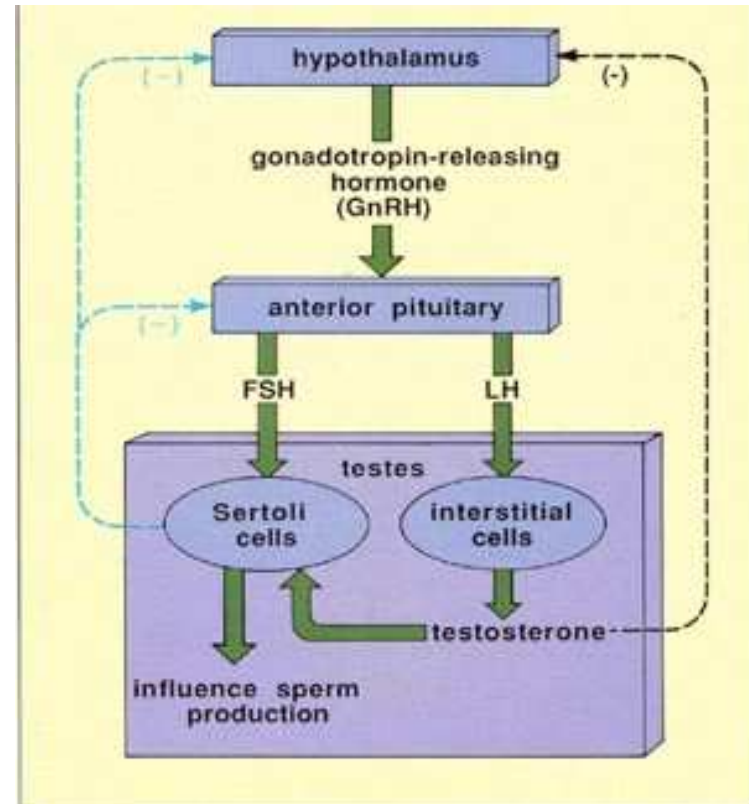
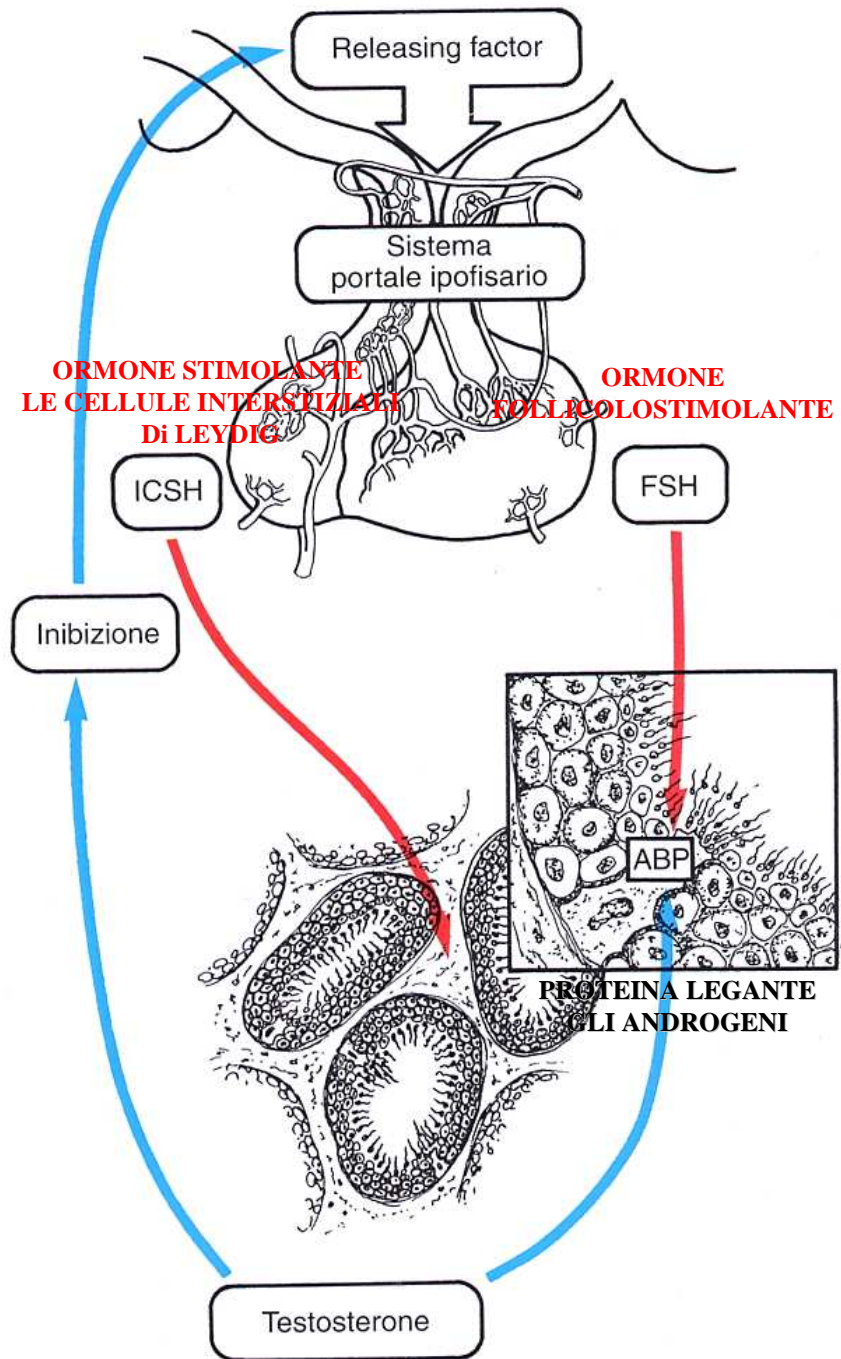
SPERMATOGONI
SPERMATOCITI DI 1° ORDINE
SPERMATIDI
SPERMIOISTOGENESI





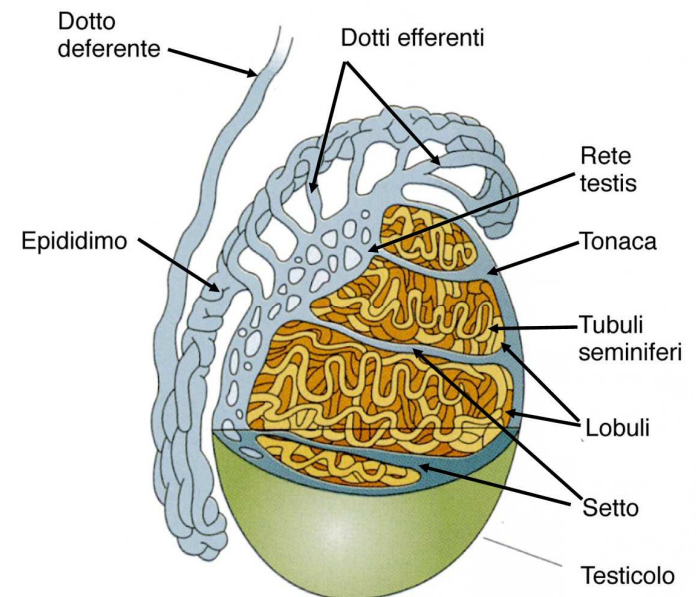
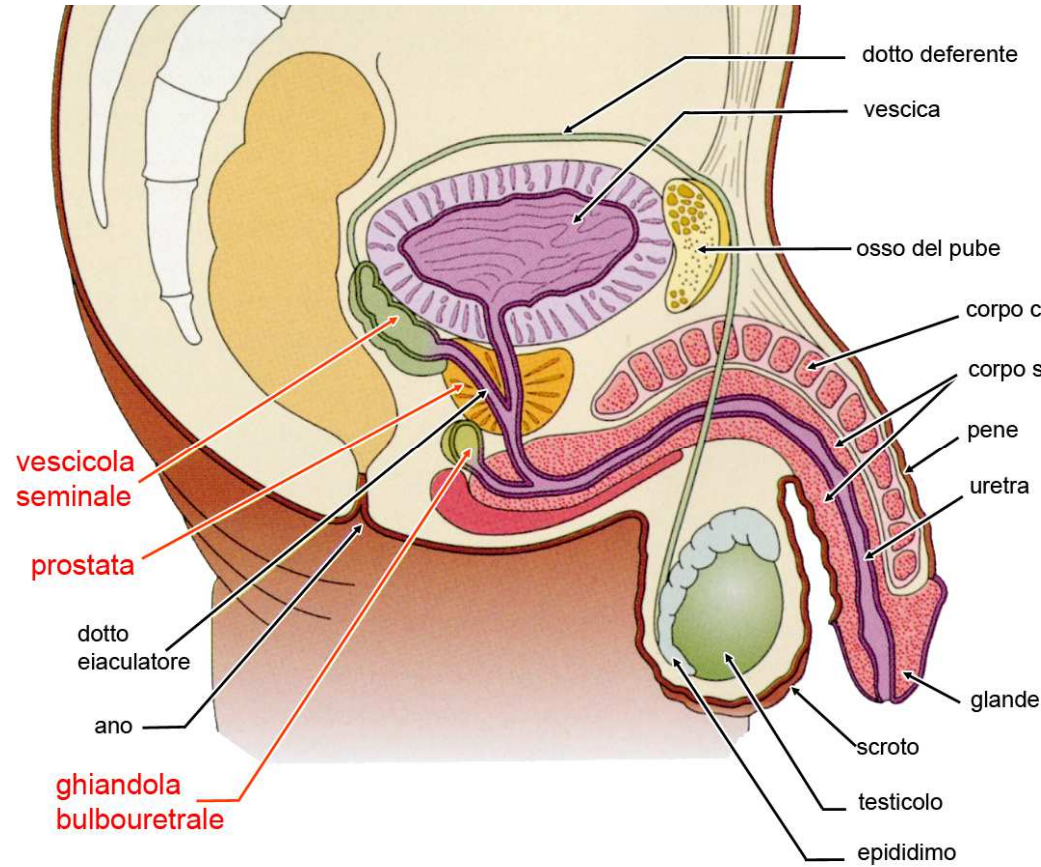


REGOLAZIONE ENDOCRINA DEL TESTICOLO

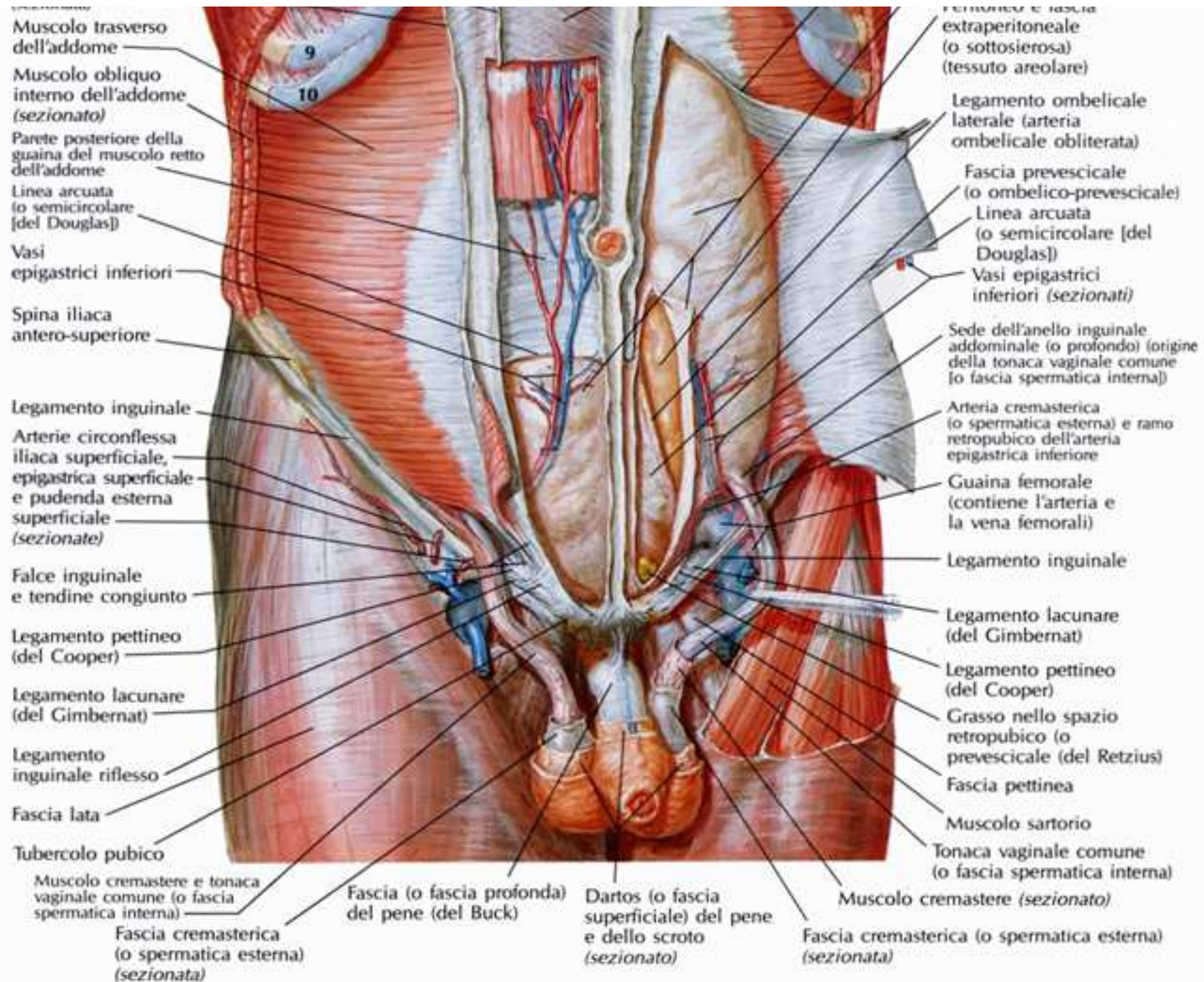


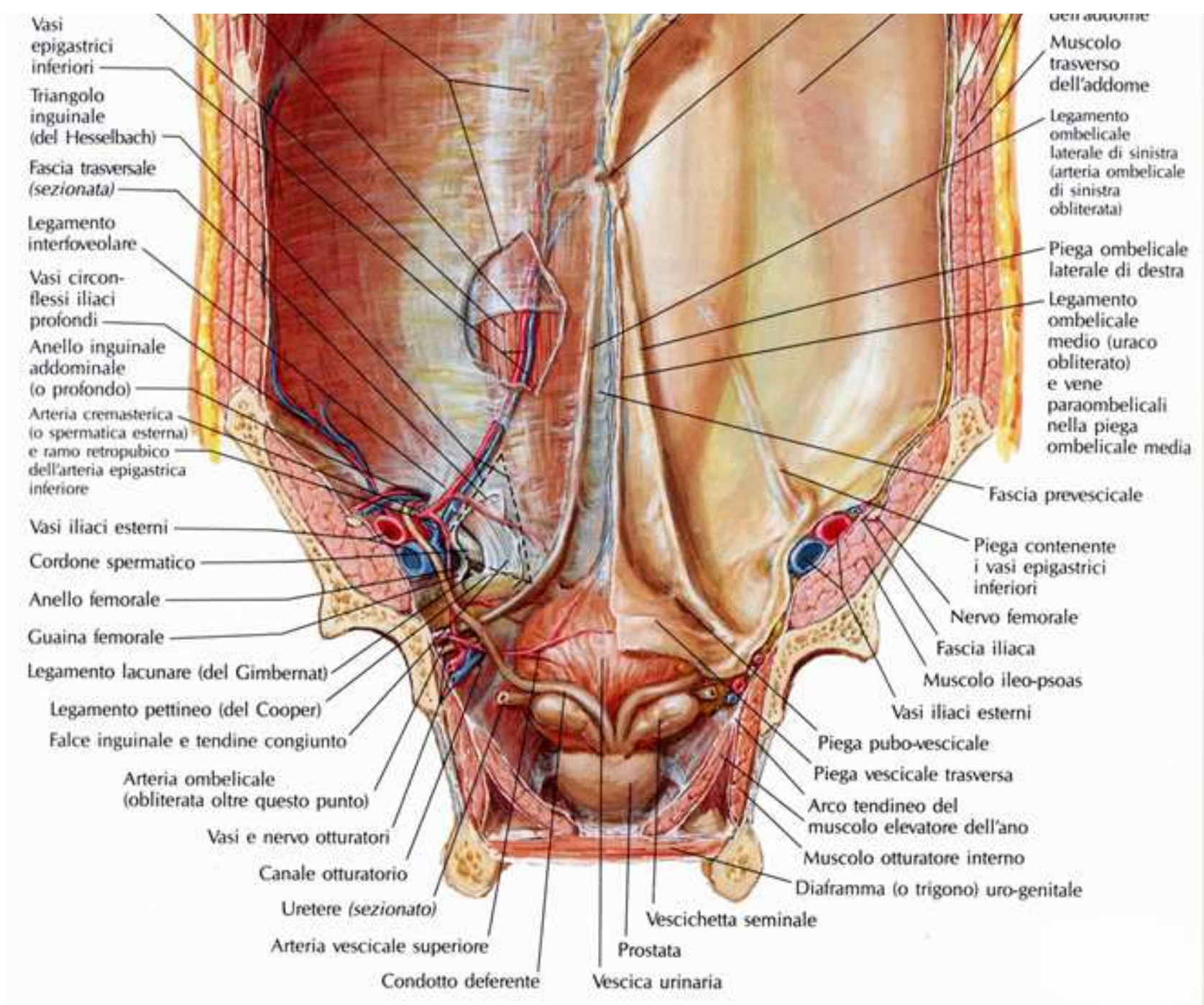
VIE SPERMATICHE

- tubuli seminiferi retti
- rete testis
- dotti efferenti
- canale dell'epididimo
- dotto deferente
- condotti eiaculatori

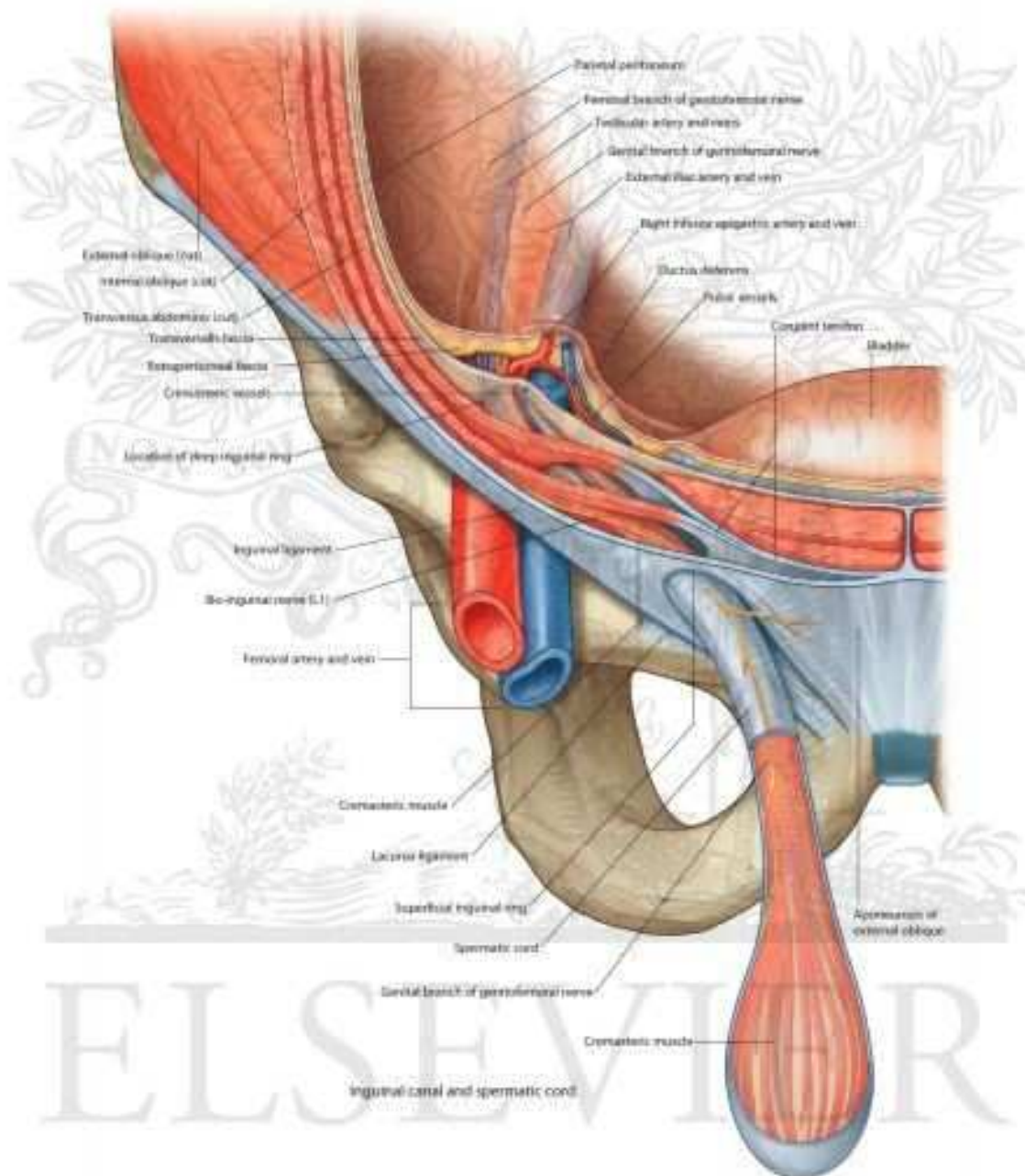


martedì 2 febbraio 2016





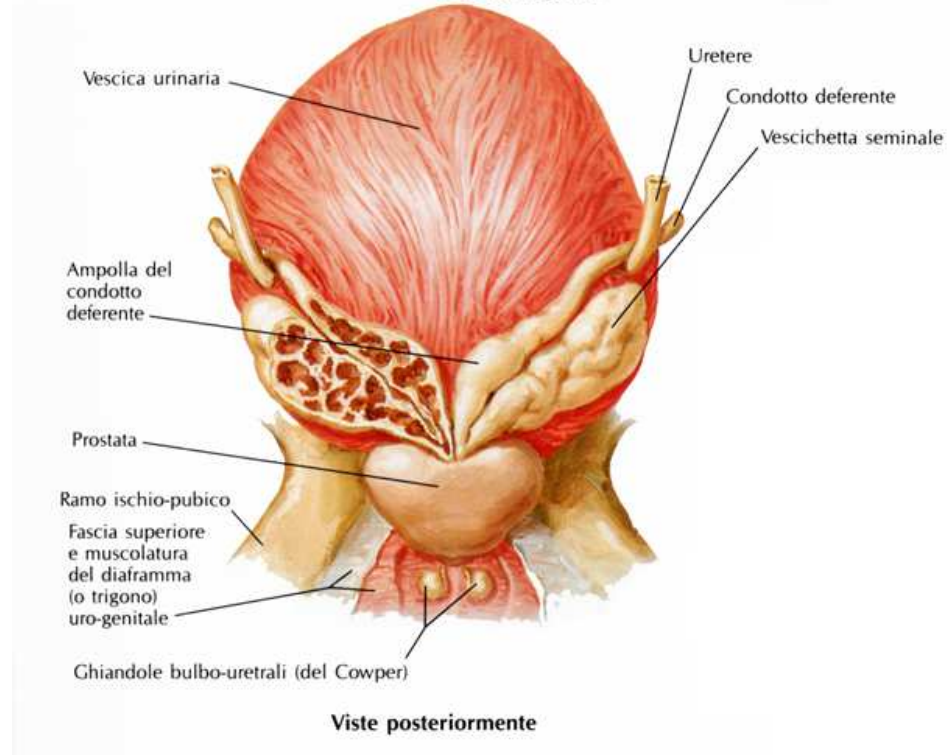
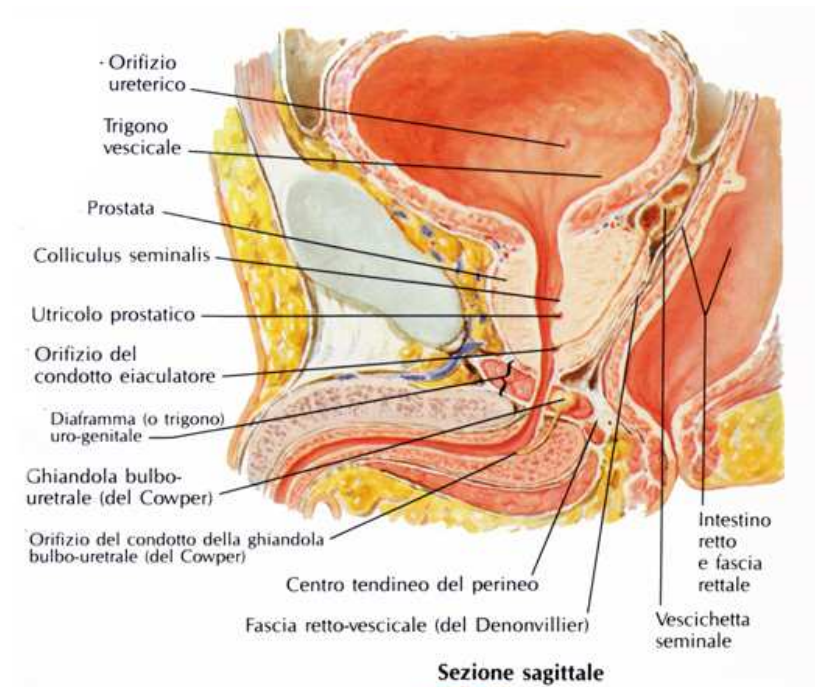
Inguinal canal



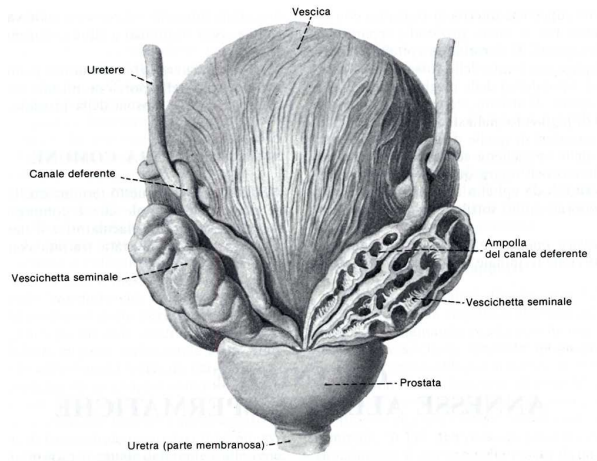
martedì 2 feb

16

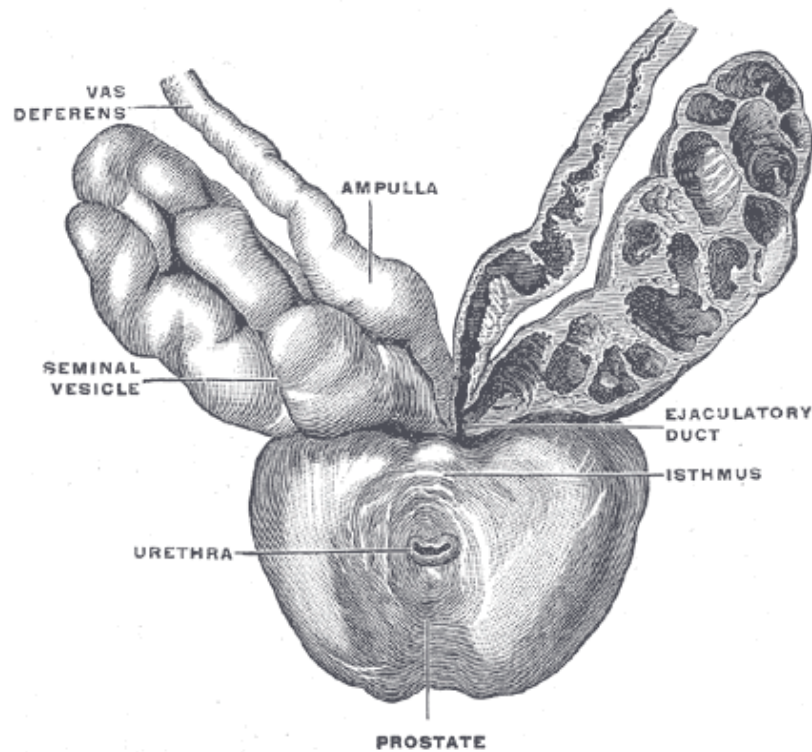
**GHIANDOLE ANNESSE
 VESCICHETTE SEMINALI
 PROSTATA
 BULBO URETRALI DI COWPER**



martedì 2 febbraio 2016



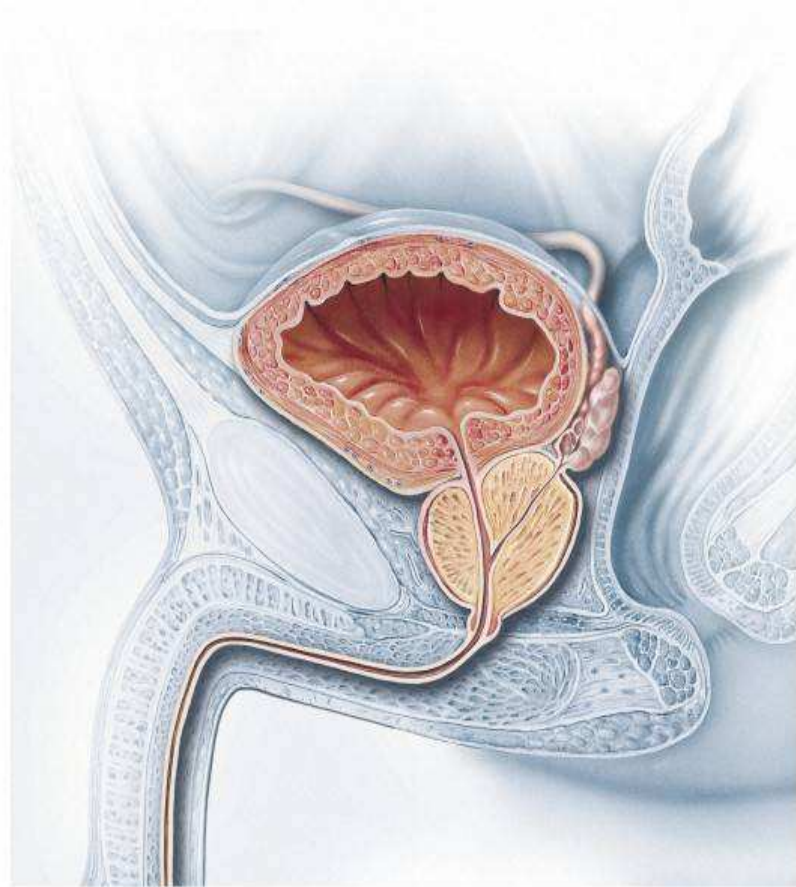
VEVICCHETTE SEMINALI



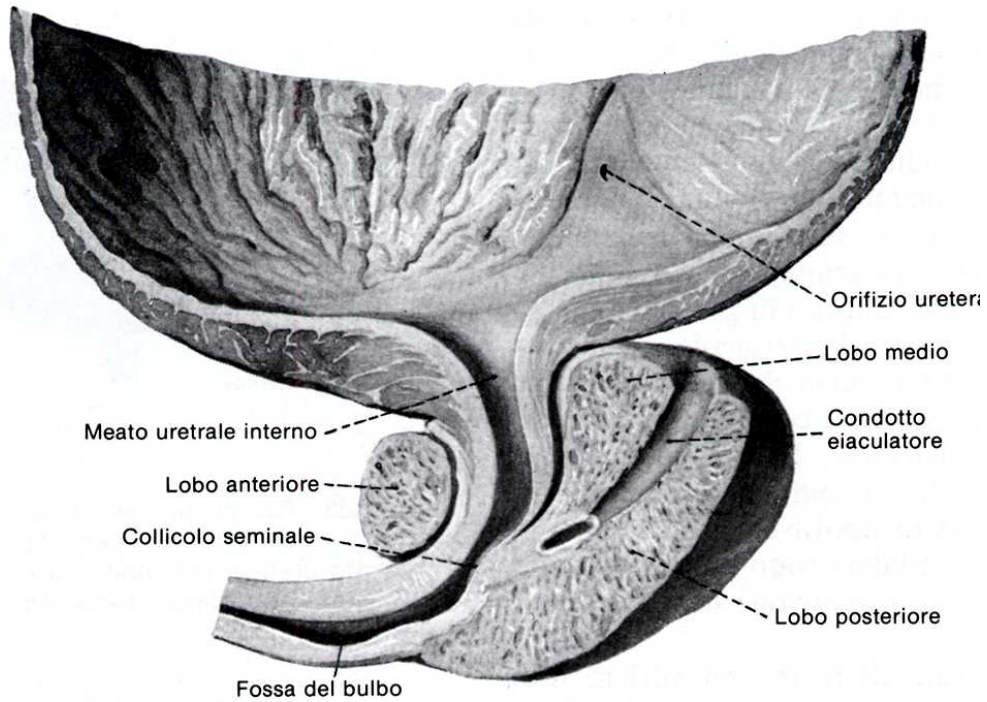
Vescichette seminali:
6,5-7,5 cm
conformazione labirintica

Producono circa il 70 % del liquido seminale
fruttosio
proteine
ac citrico
lipofuscina

PROSTATA

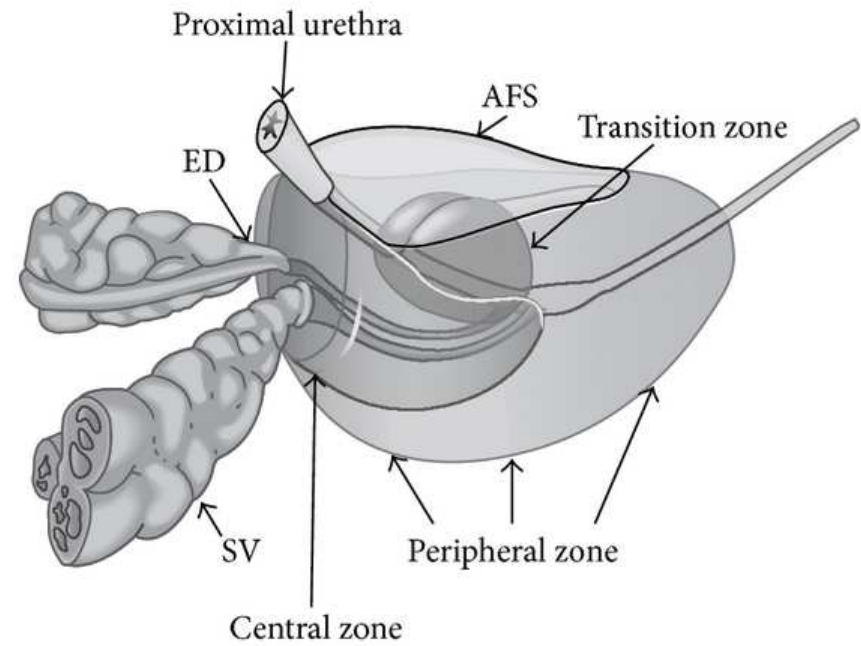
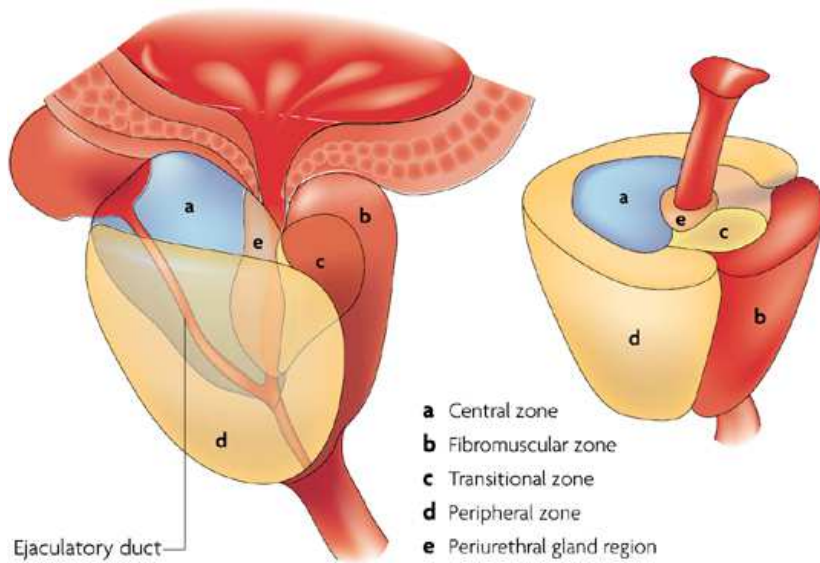


Gh tubuloalveolari (circa 40)
Corpi sferici calcificati (amilacei)
Secreto 30 % del liquido seminale
enzimi
prostaglandine
acido citrico
zinco

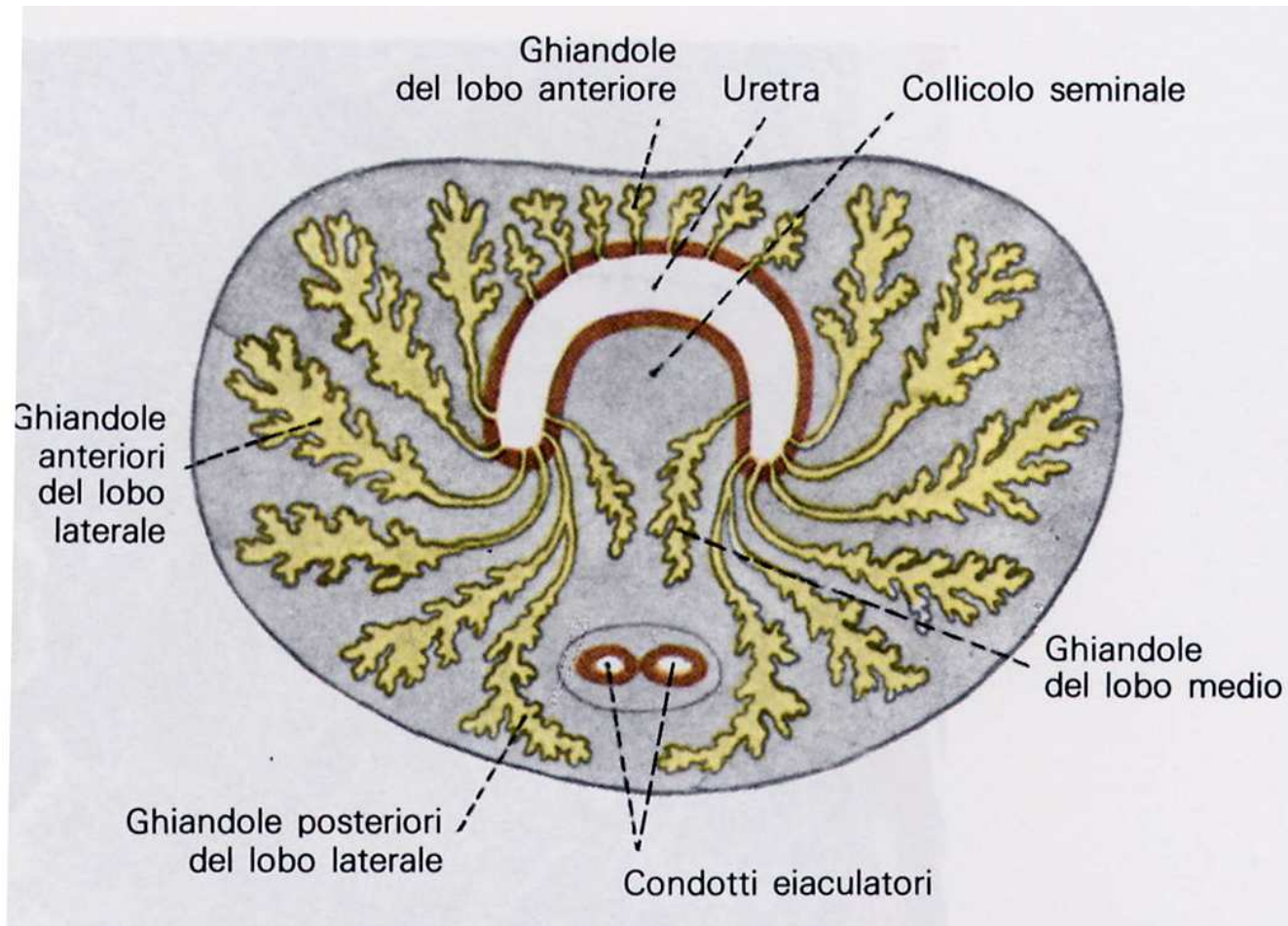


PROSTATA

Lobo Anteriore
Lobo Medio
Lobo Posteriore



PROSTATA



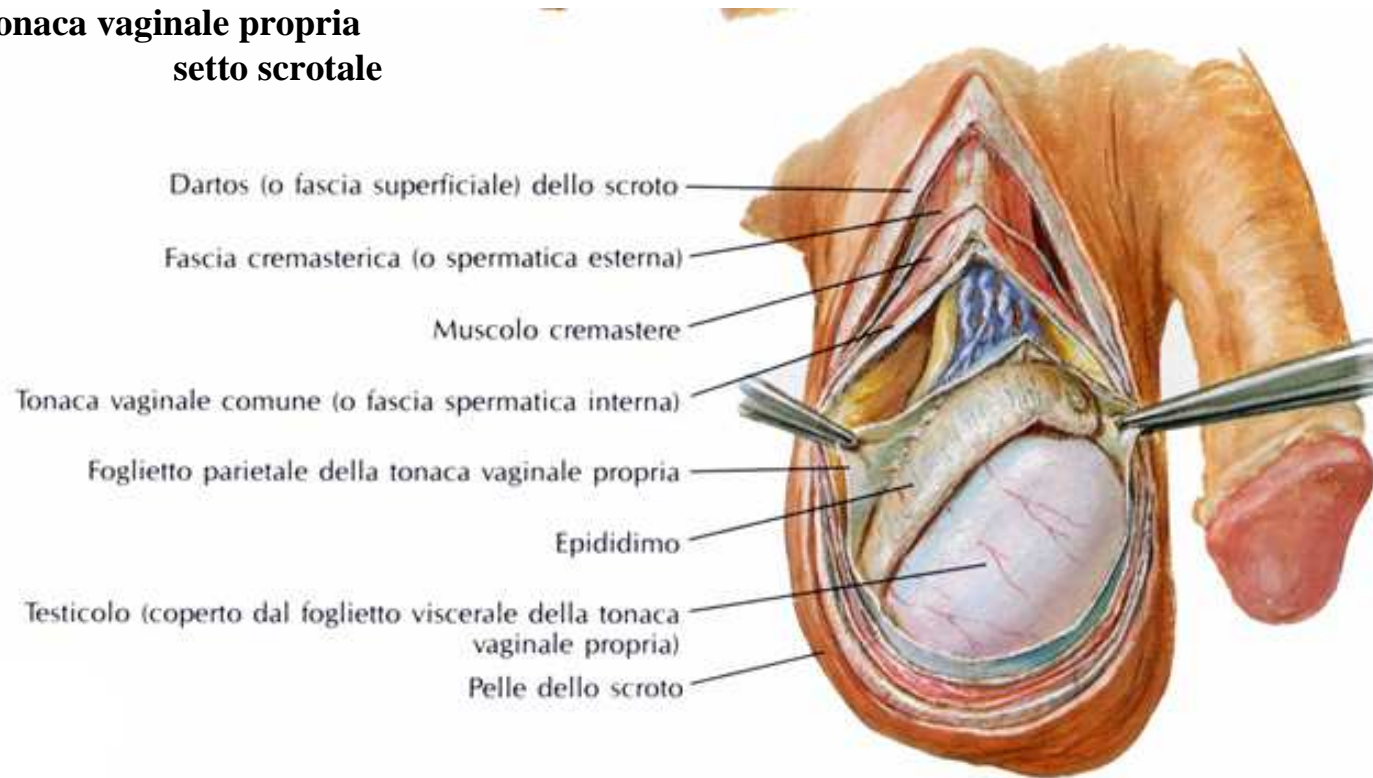
ORGANI GENITALI ESTERNI

SCROTO

- cute
- tonaca dartos
- fascia cremasterica
- muscolo cremastere
- tonaca vaginale comune
- tonaca vaginale propria
- setto scrotale

SCROTO

PENE



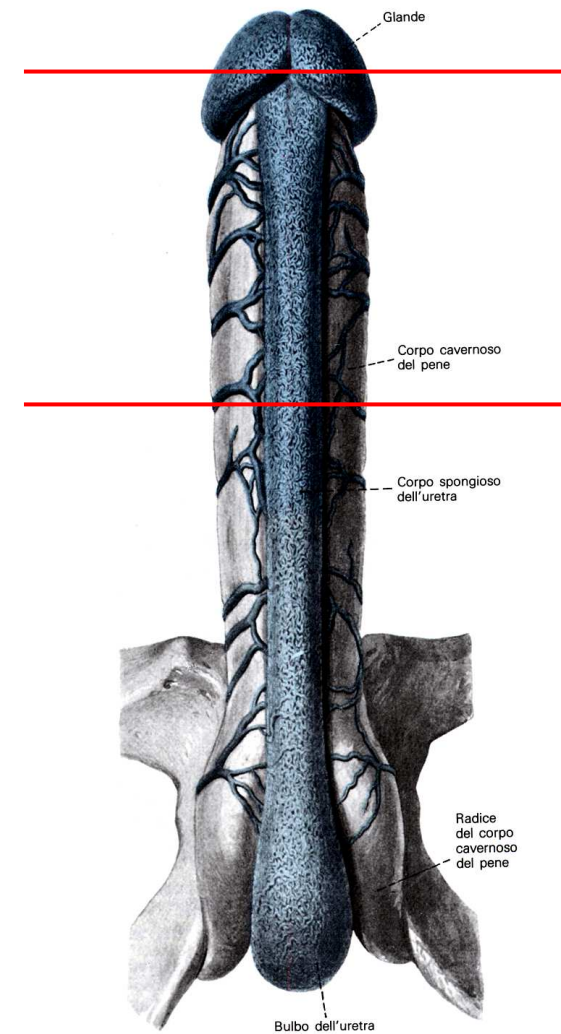
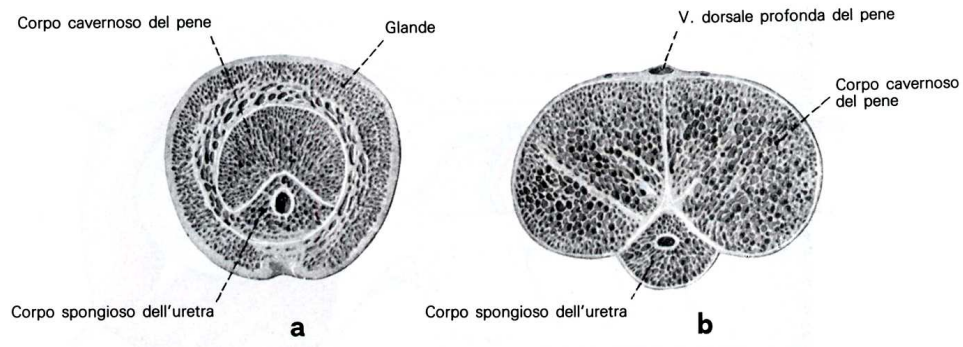
PENE

Organo copulatore

corpi cavernosi del pene

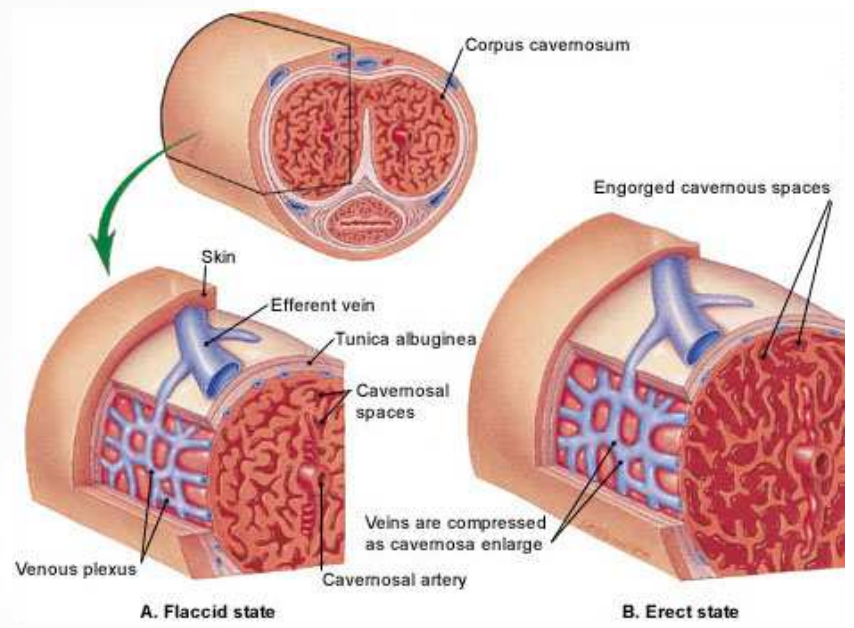
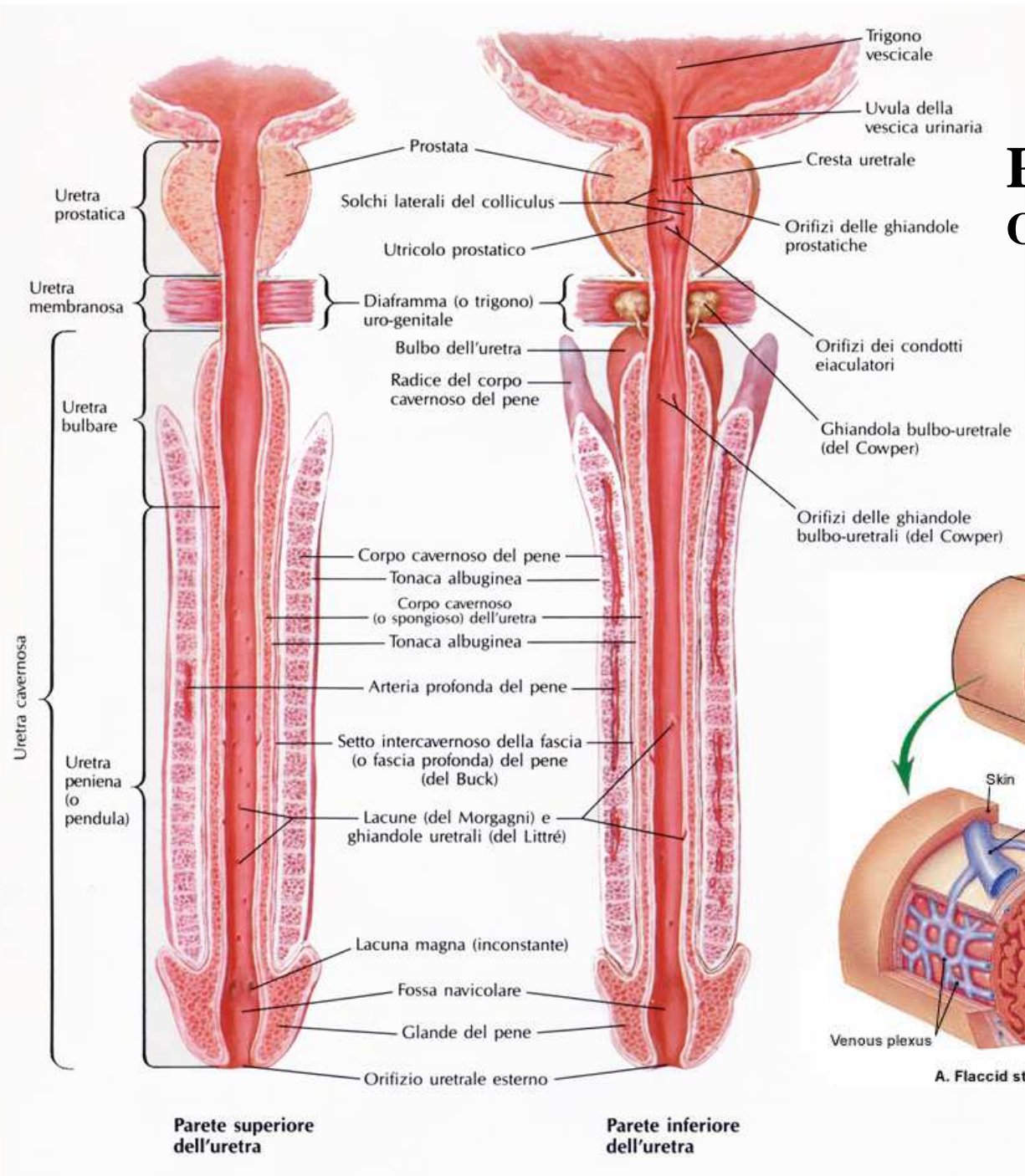
corpo cavernoso dell'uretra

glande



PENE

Organo copulatore
corpi cavernosi del pene
corpi cavernosi dell'uretra
glande



VACOLARIZZAZIONE DEL PENE

