



**Università degli studi di  
Bari**

**Corso di Laurea in:  
INFERMIERISTICA  
FISIOTERAPIA**

**E**

**IGIENE DENTALE**

**Facoltà di Medicina e Chirurgia**

**CORSO DI  
ANATOMIA UMANA**

# Anatomia Umana

- Anatomia Macro- e Microscopica.
  - **Apparato locomotore**
  - **Apparato circolatorio**
  - Apparato emolinfopoietico
  - Apparato uropoietico
  - Apparato respiratorio
  - Apparato digerente
  - Apparato endocrino
  - Apparato genitale maschile
  - Apparato genitale femminile
  - Apparato nervoso
  - Apparato tegumentario

# APPARATO CIRCOLATORIO SANGUIFERO

SISTEMA A CIRCUITO CHIUSO

CUORE

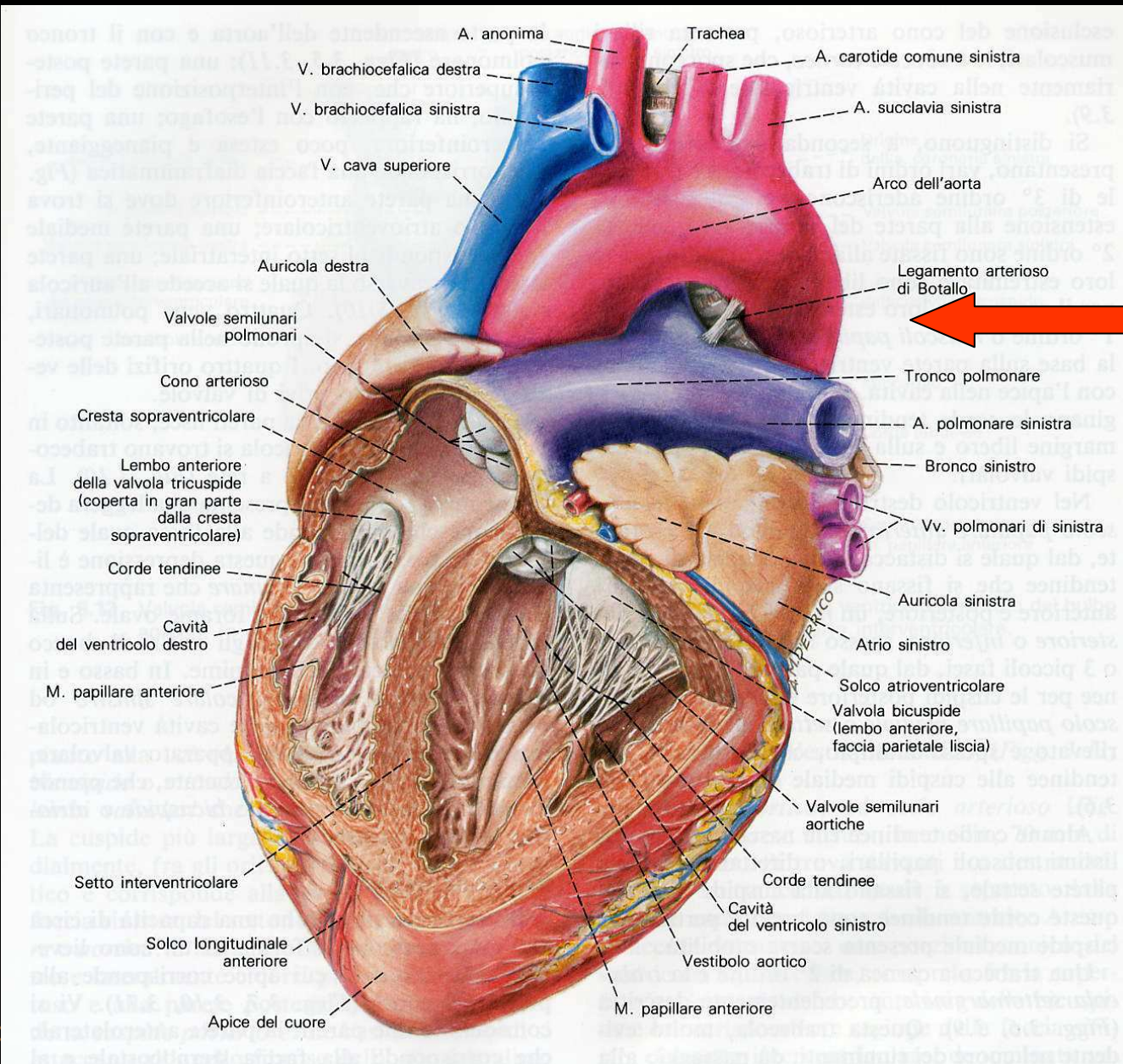
VASI

Arterie – Capillari – Vene

GRANDE CIRCOLAZIONE (o circolazione sistemica)

PICCOLA CIRCOLAZIONE (o circolazione polmonare)

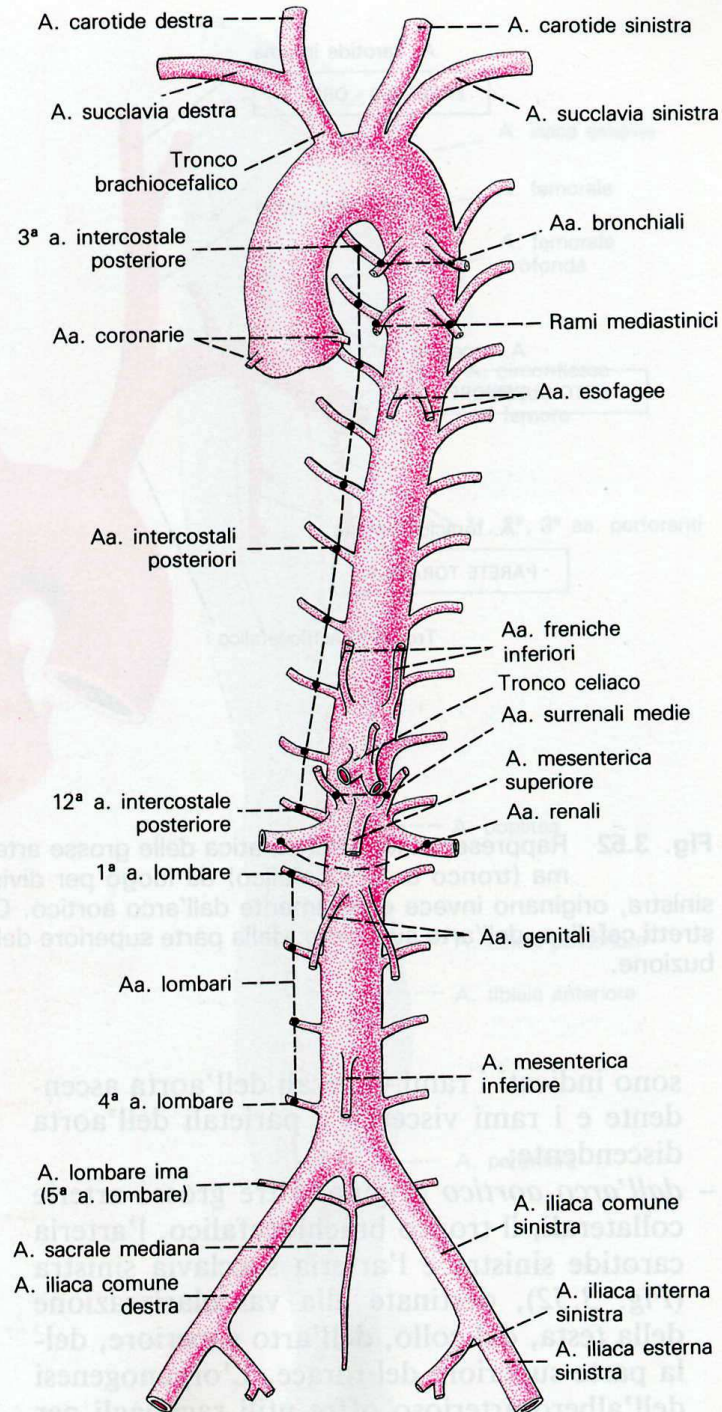
# PICCOLA CIRCOLAZIONE



# ARTERIE DELLA CIRCOLAZIONE SISTEMICA

- **AORTA ASCENDENTE**
  - FORMA, POSIZIONE, DECORSO, RAMI COLLATERALI
  
- **ARCO DELL'AORTA**
  - FORMA, POSIZIONE, DECORSO, RAMI COLLATERALI

# Arteria AORTA



## AORTA ASCENDENTE, AORTA TORACICA, AORTA ADDOMINALE

### TERRITORIO DI DISTRIBUZIONE

Visceri delle cavità toracica e addominale, pareti del torace e dell'addome,  
speco vertebrale, meningi e midollo spinale

**RAMI VISCERALI**

**RAMI PARIETALI**

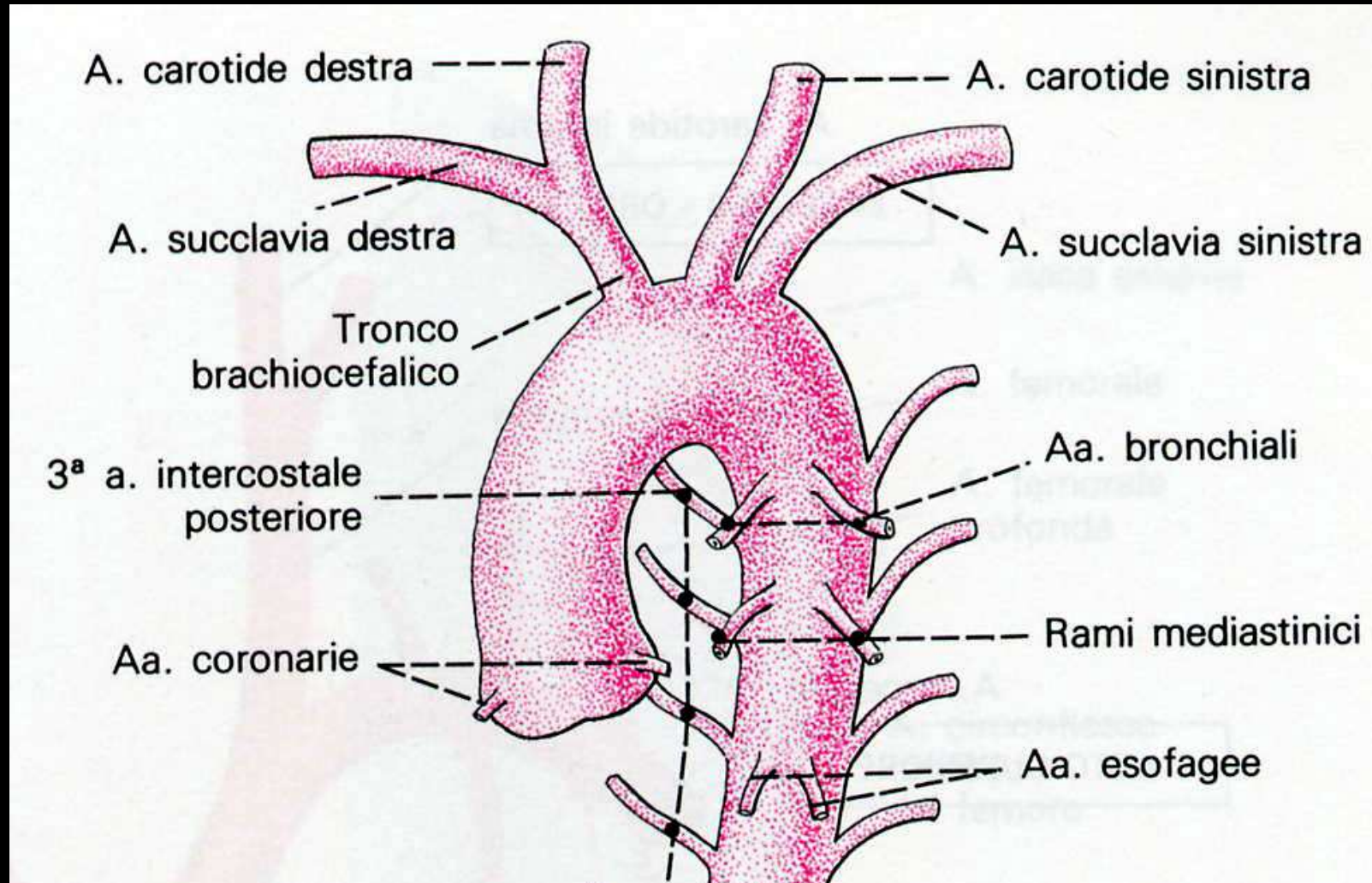
**AORTA ASCENDENTE**

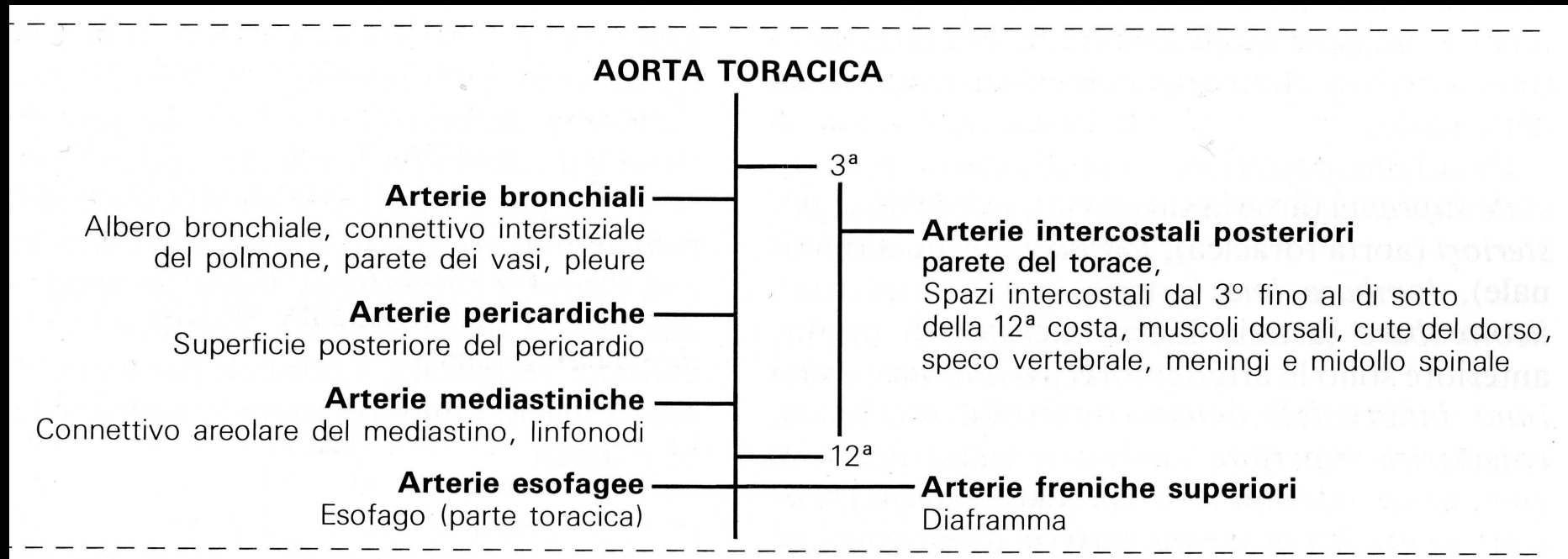
**Arterie coronarie:** Cuore



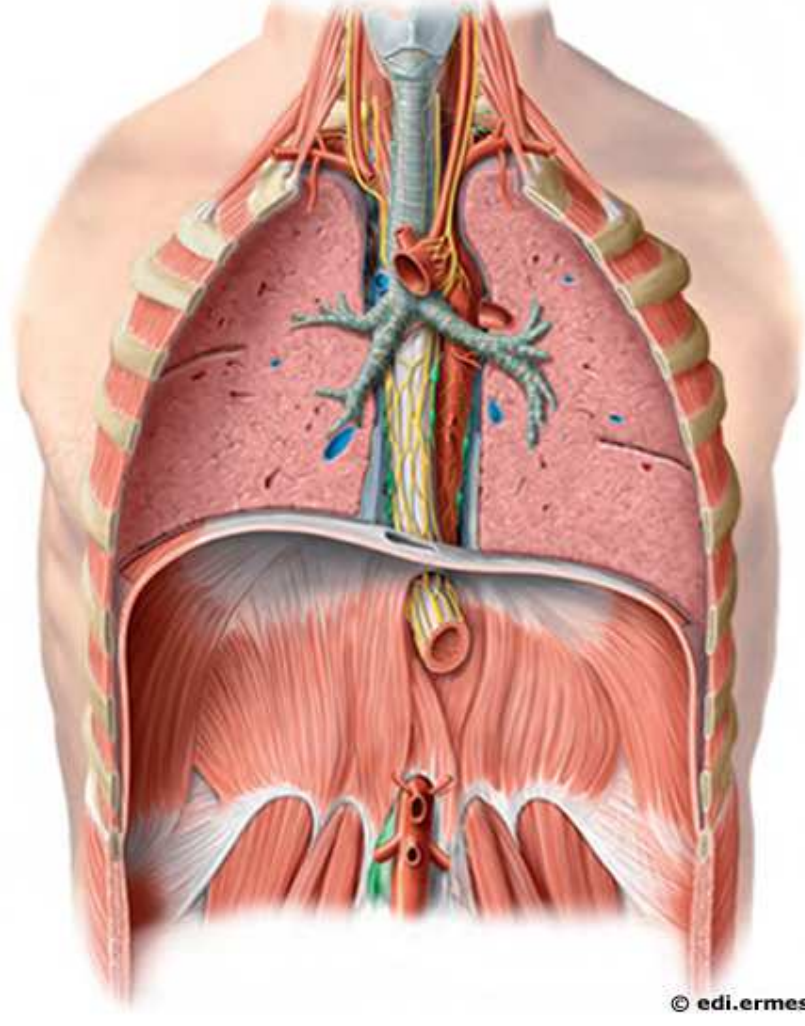
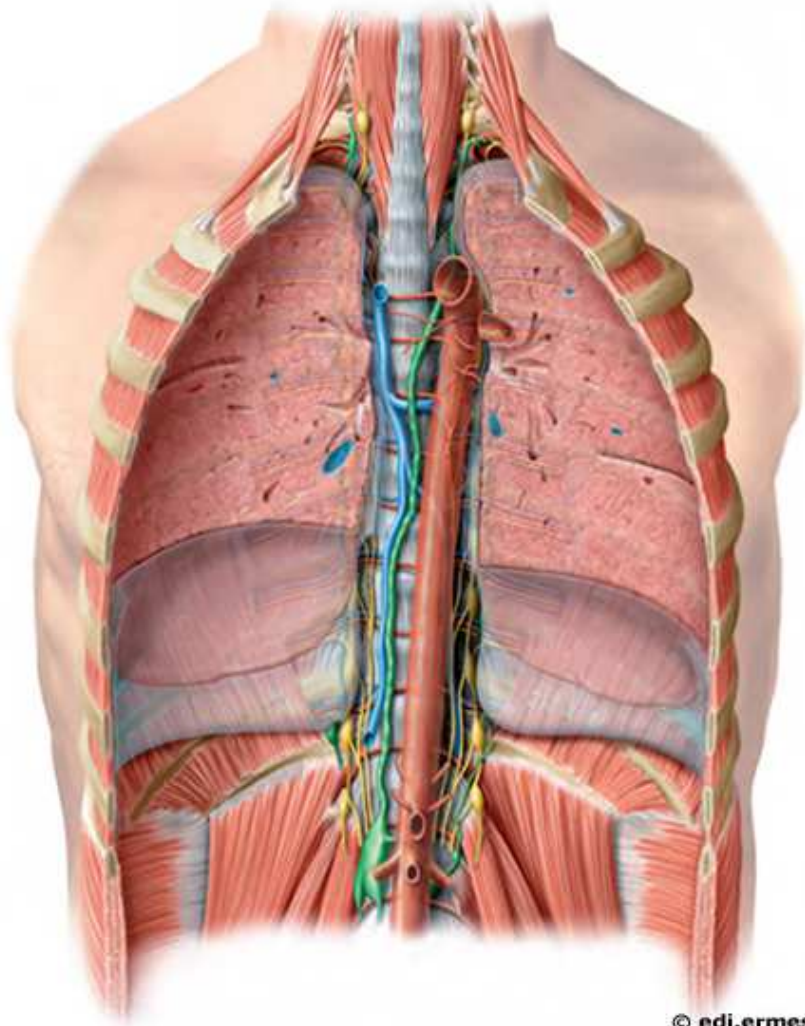


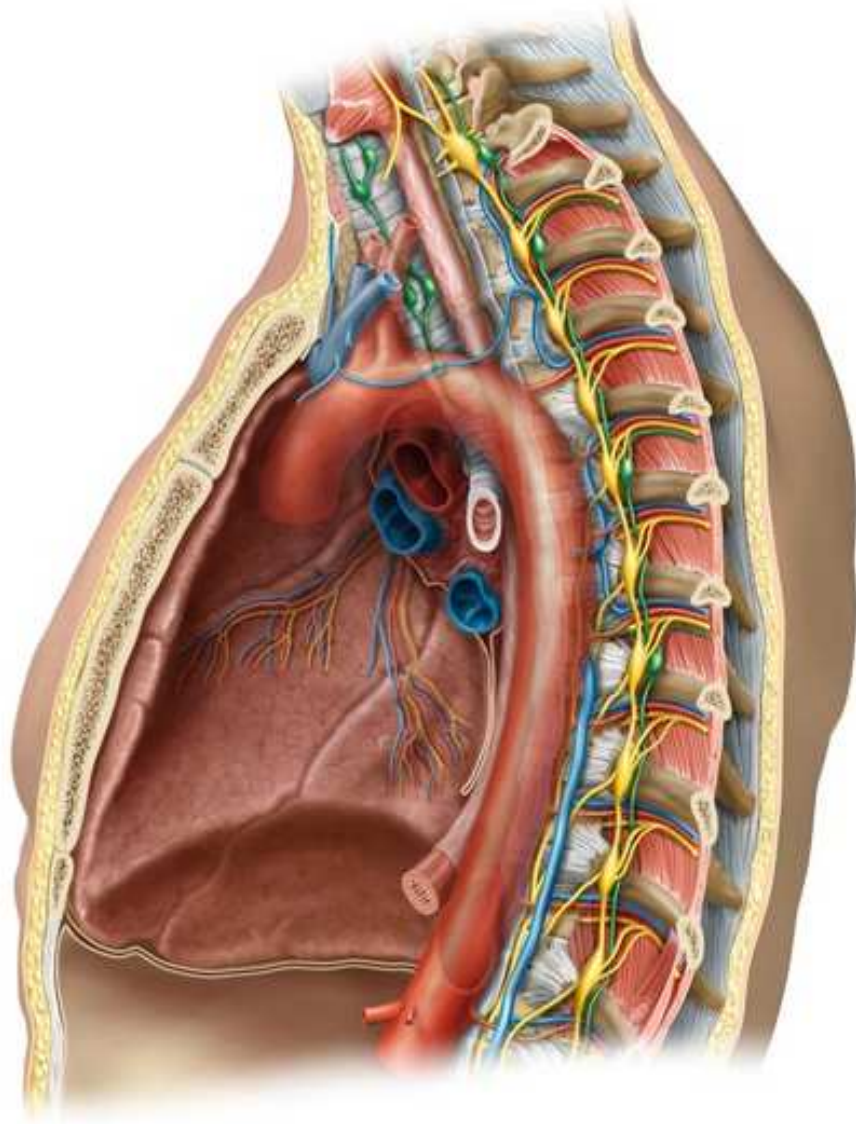
# Arteria AORTA - arco

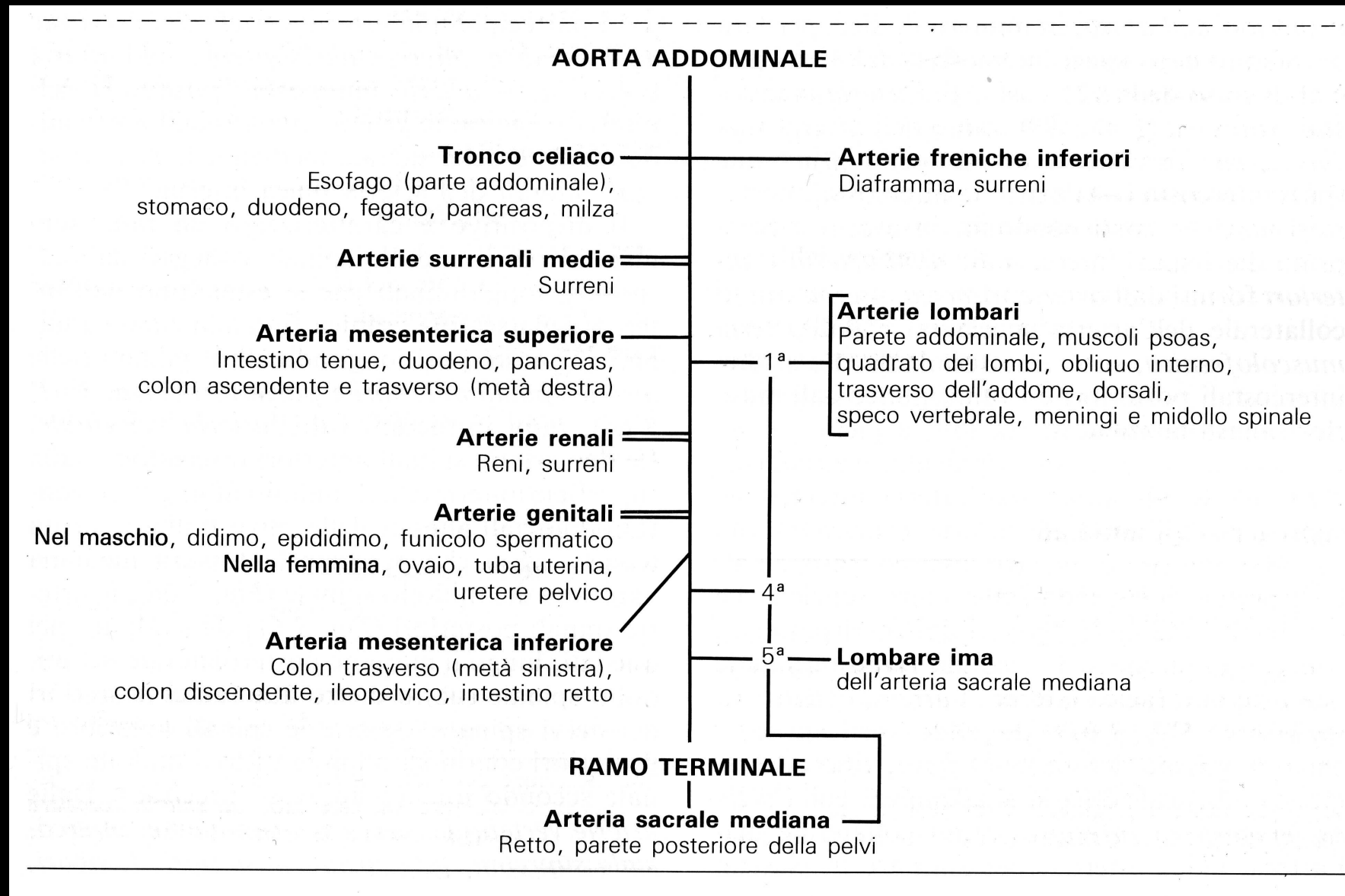




# Arteria AORTA - toracica

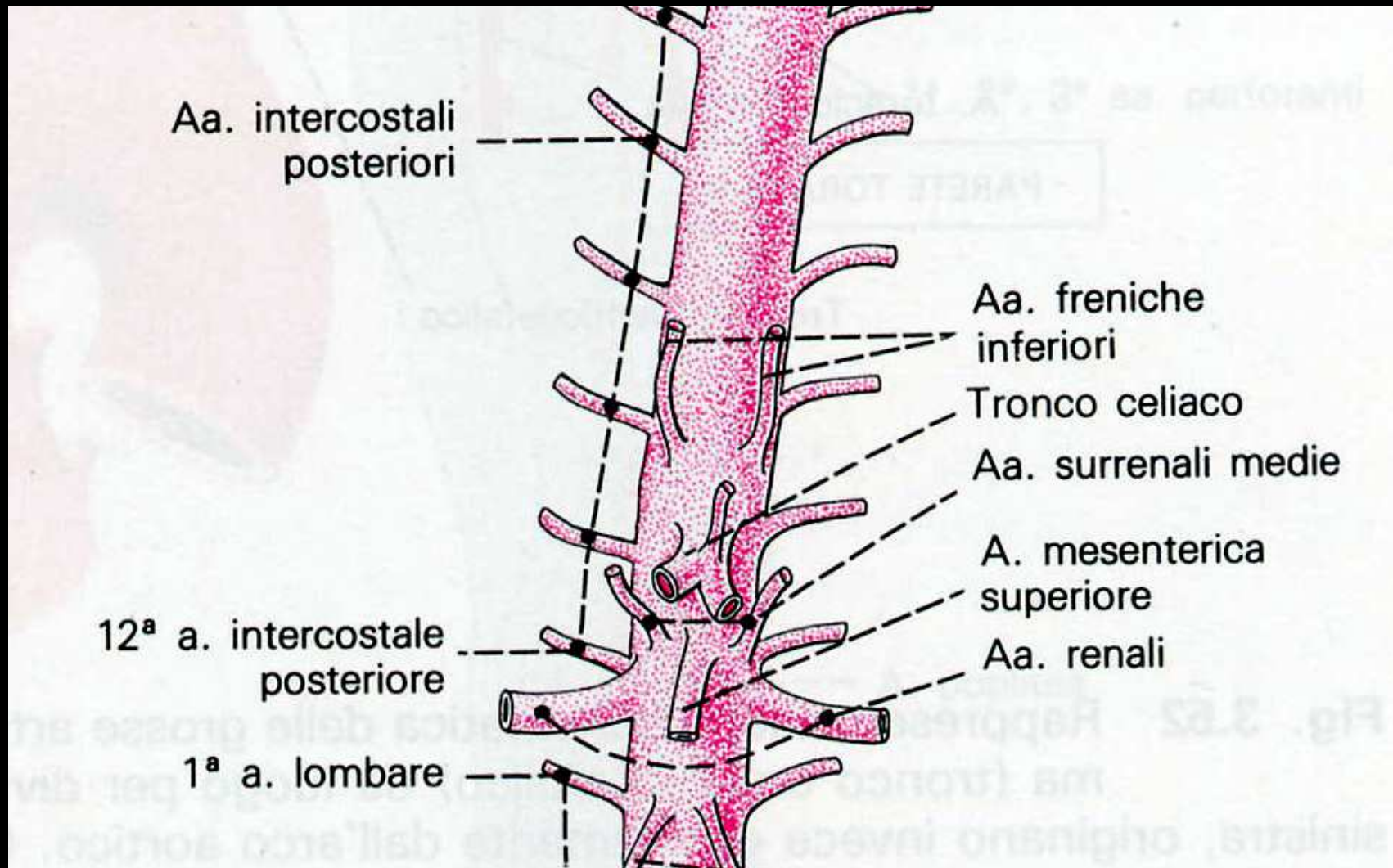






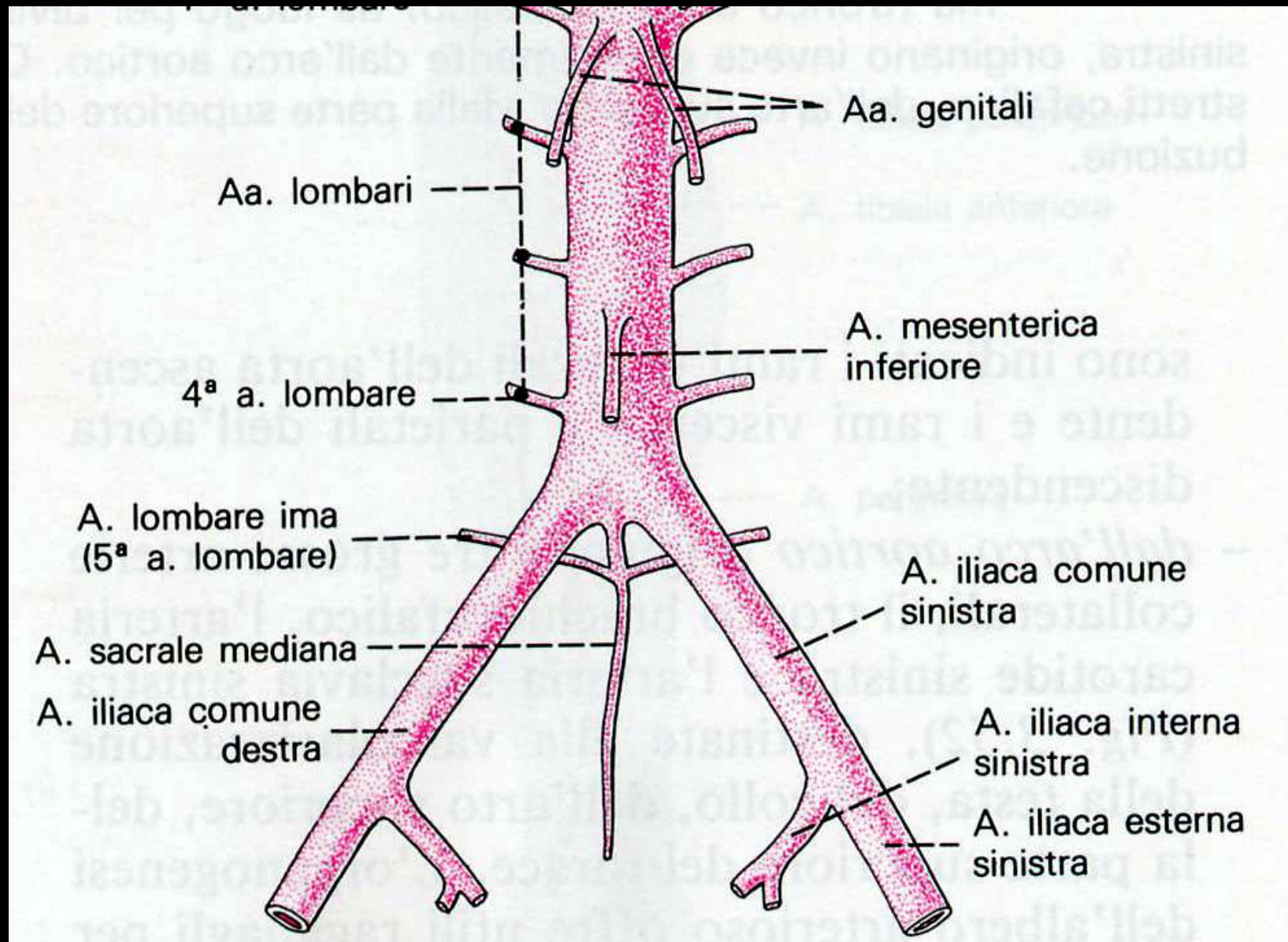
# Arteria AORTA - addominale

14

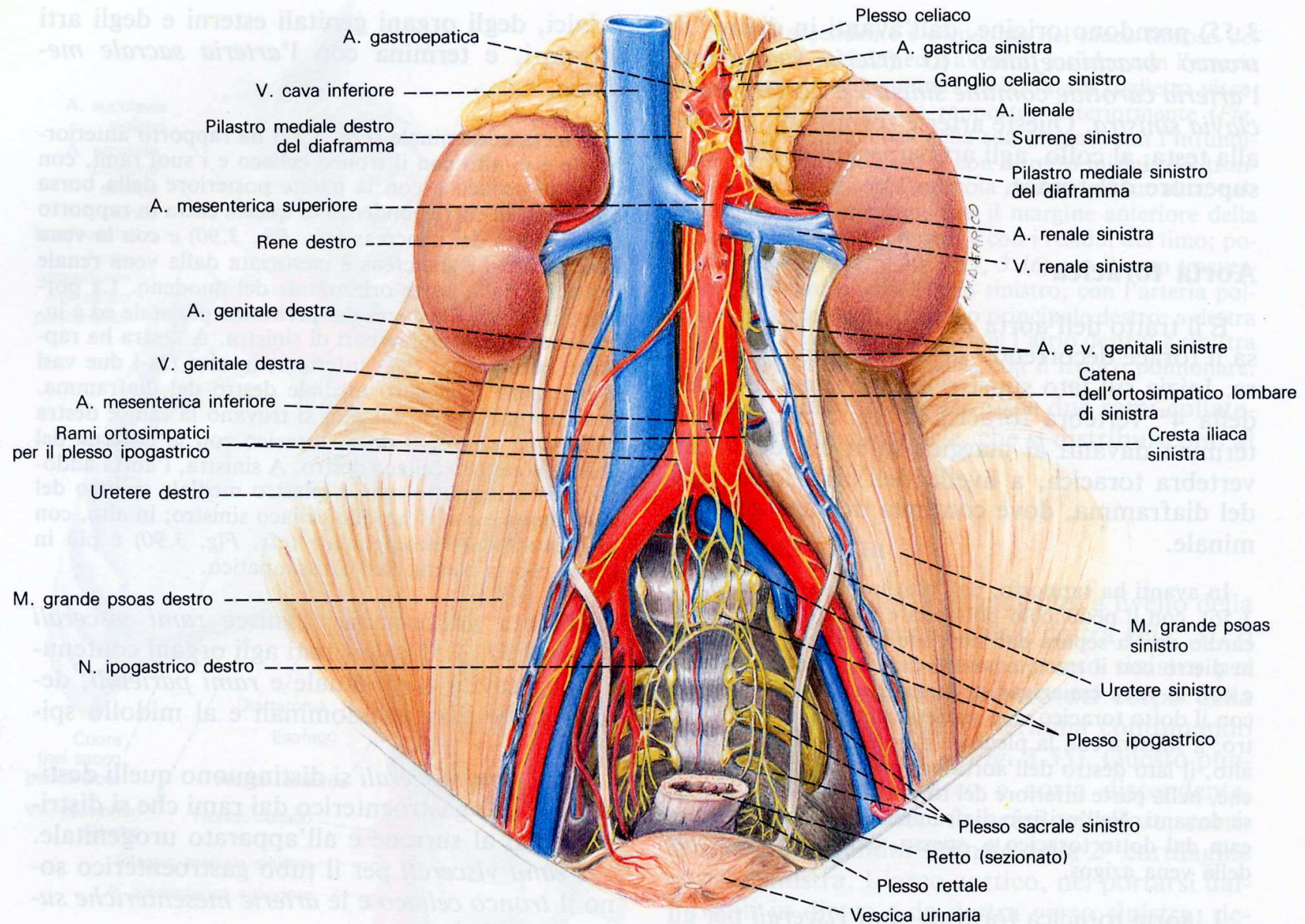


# Arteria AORTA - addominale

15

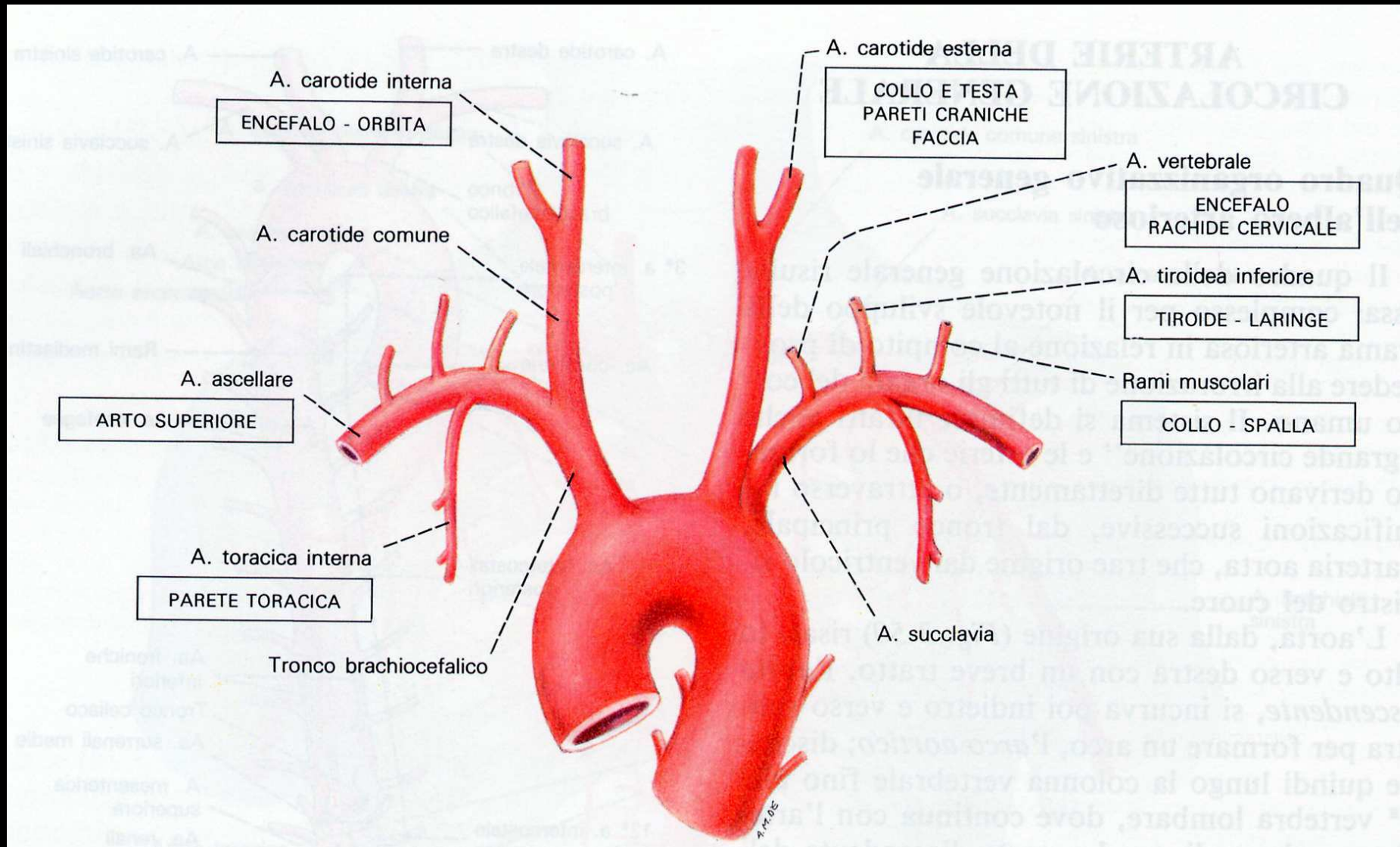


# Arteria AORTA - addominale

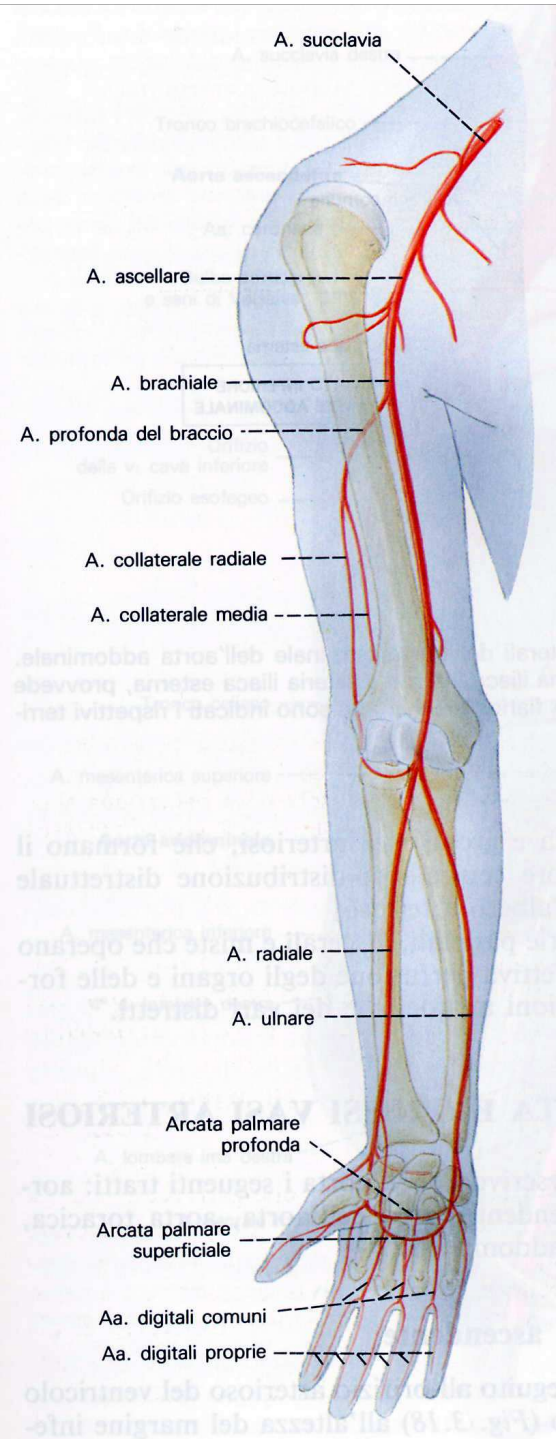


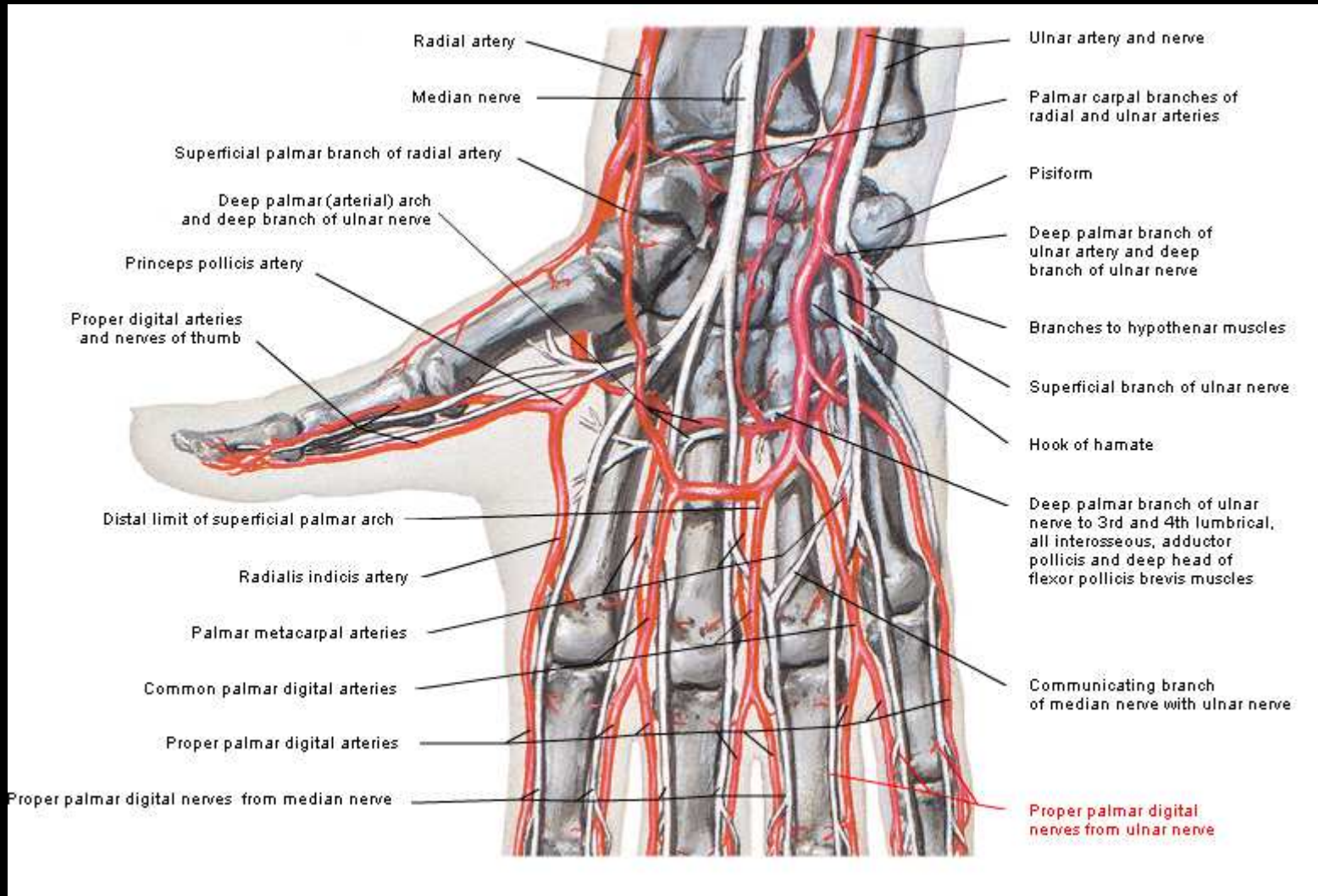


# Arteria AORTA - arco



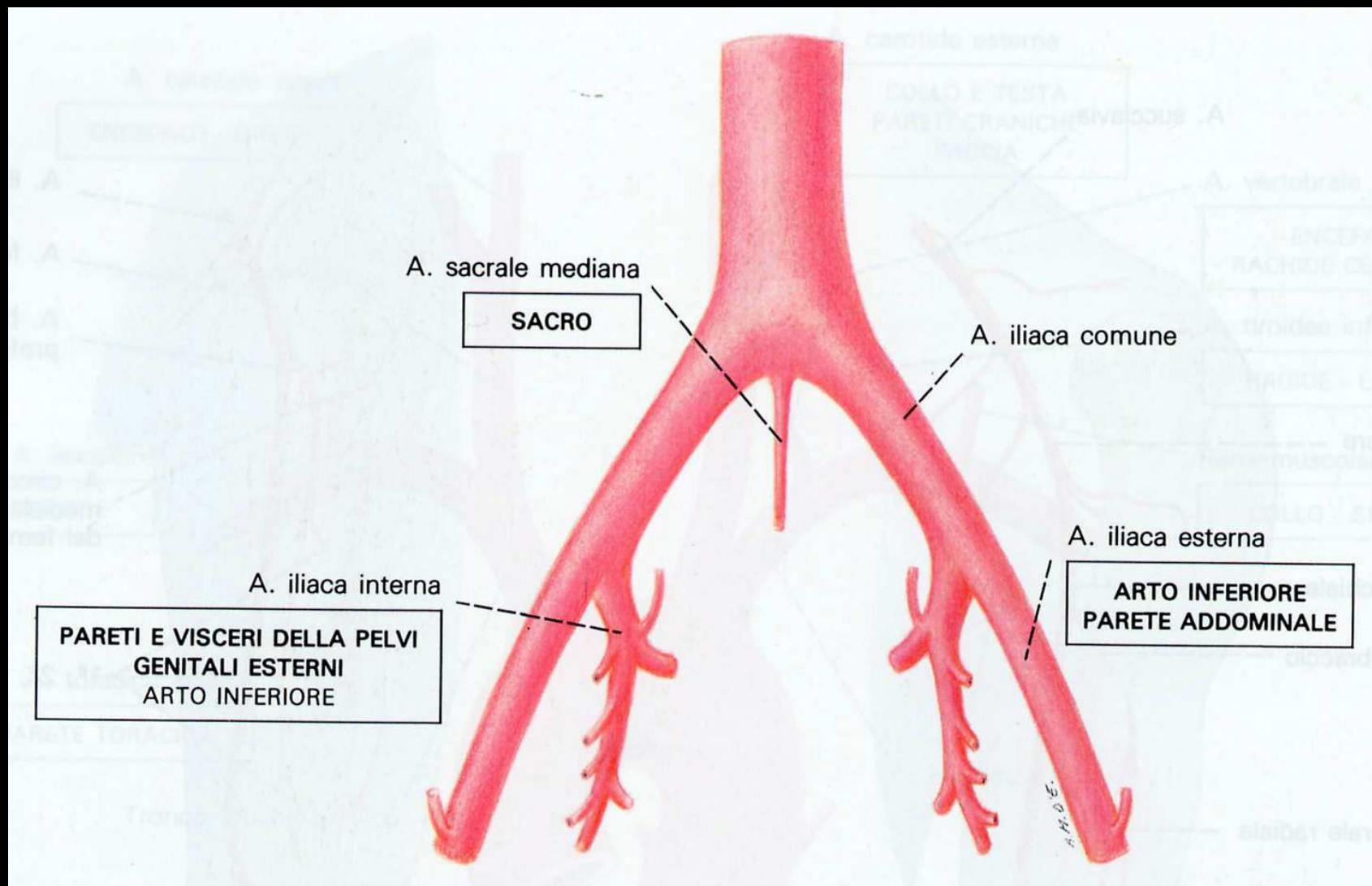
# Vascularizzazione arteriosa dell'arto superiore



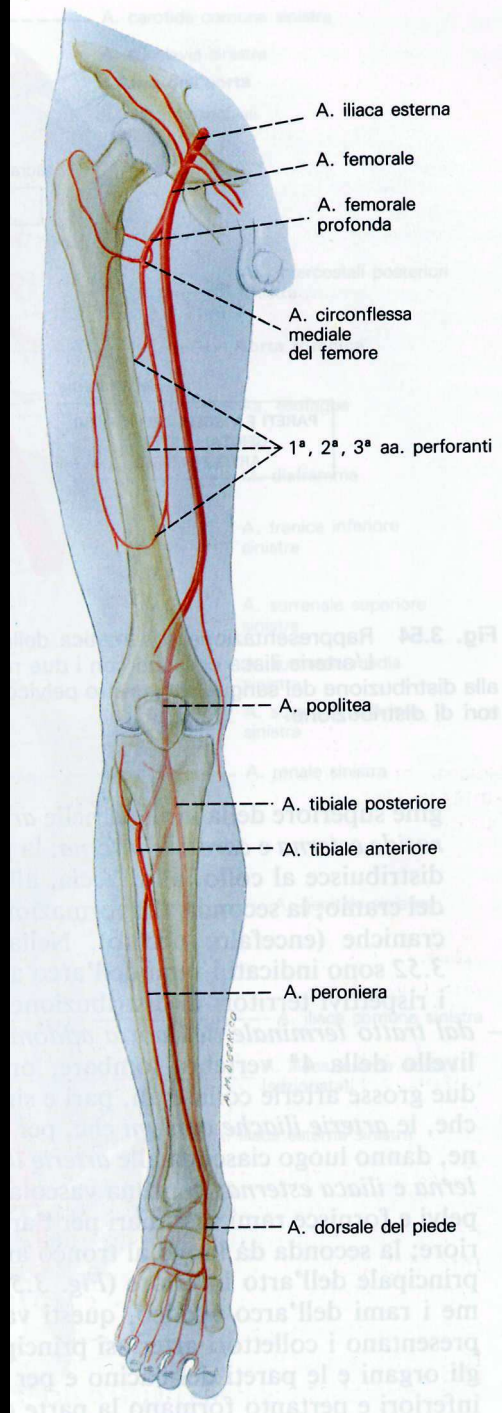


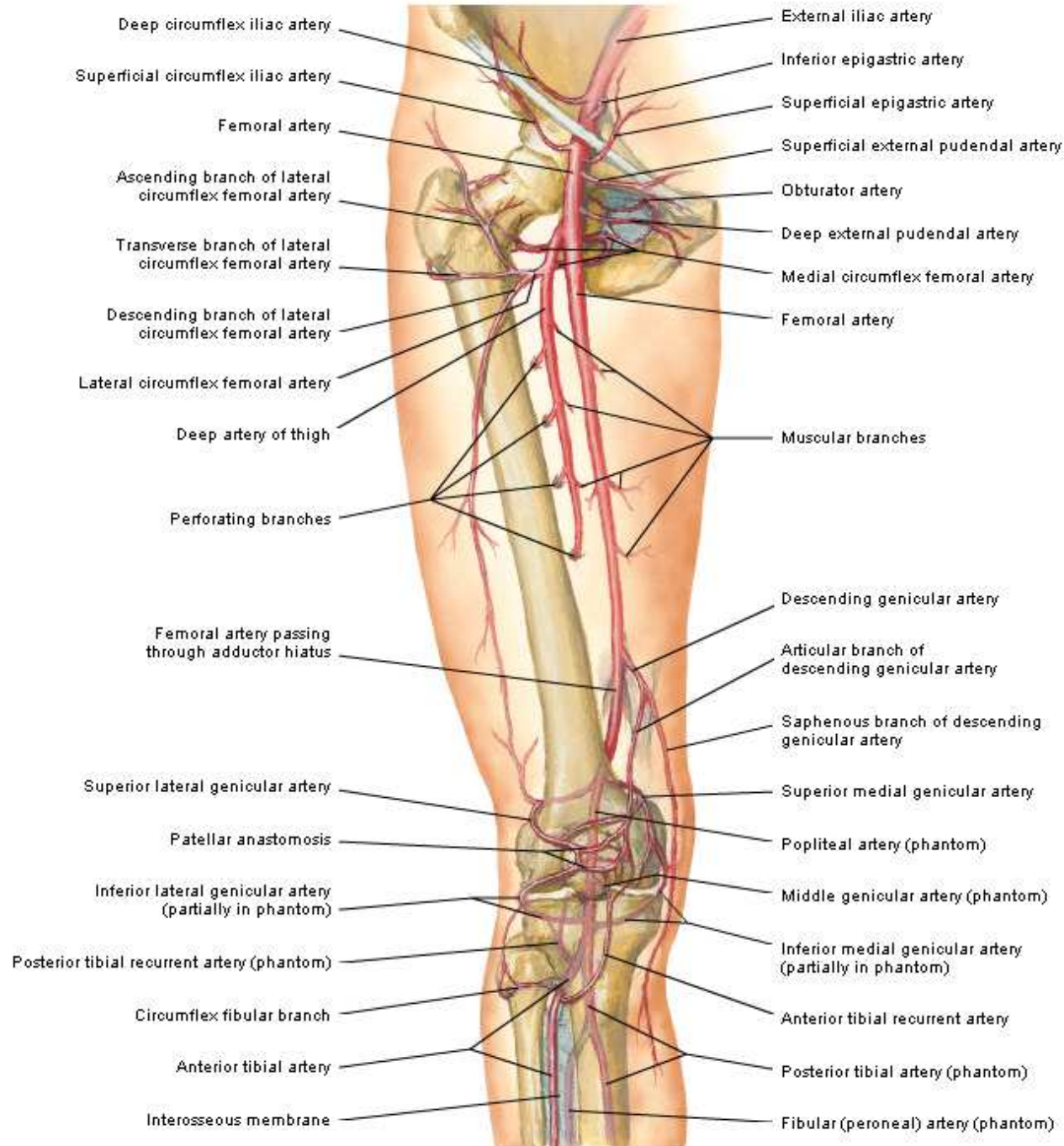
# Arteria AORTA - terminale

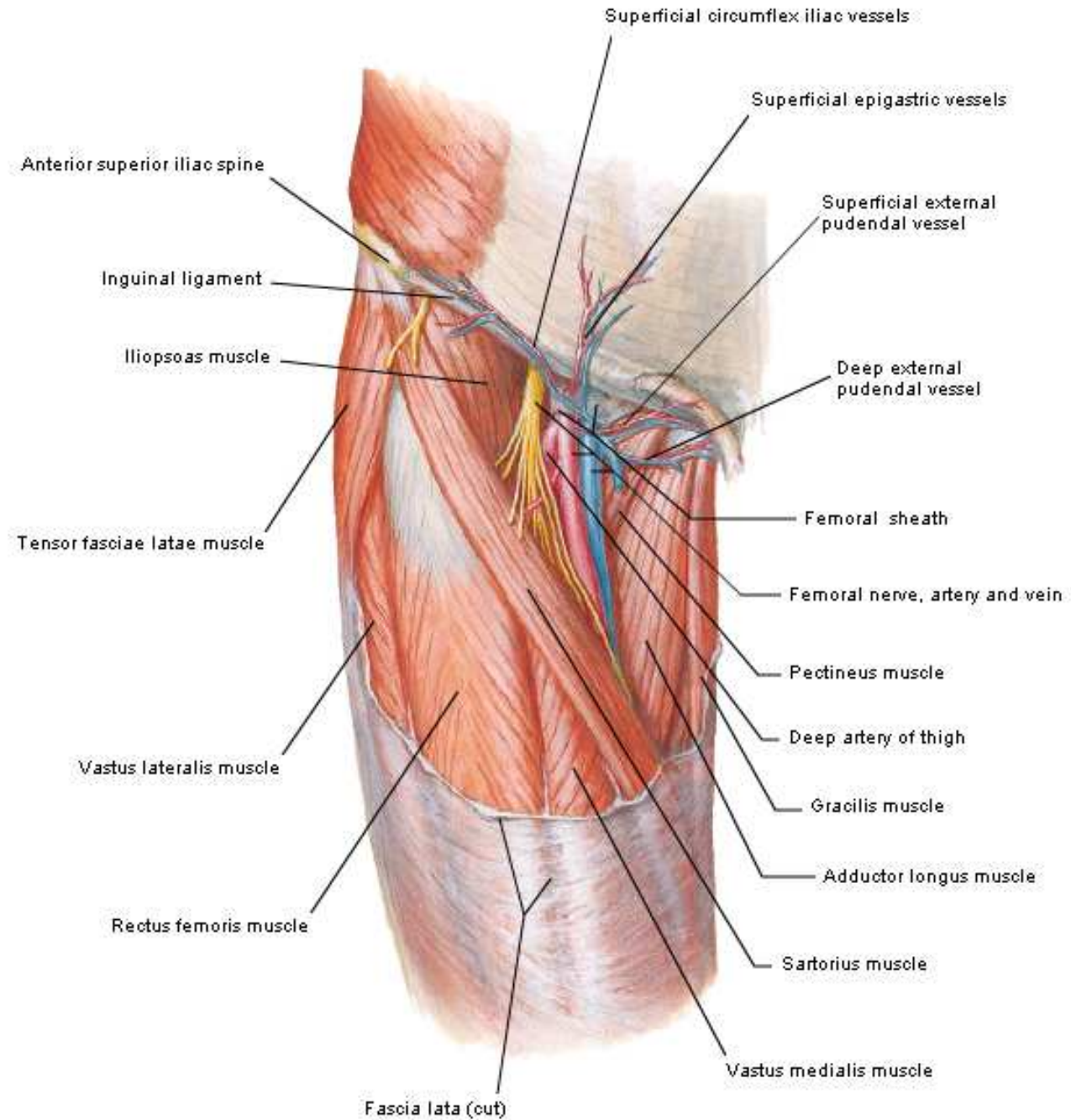
20

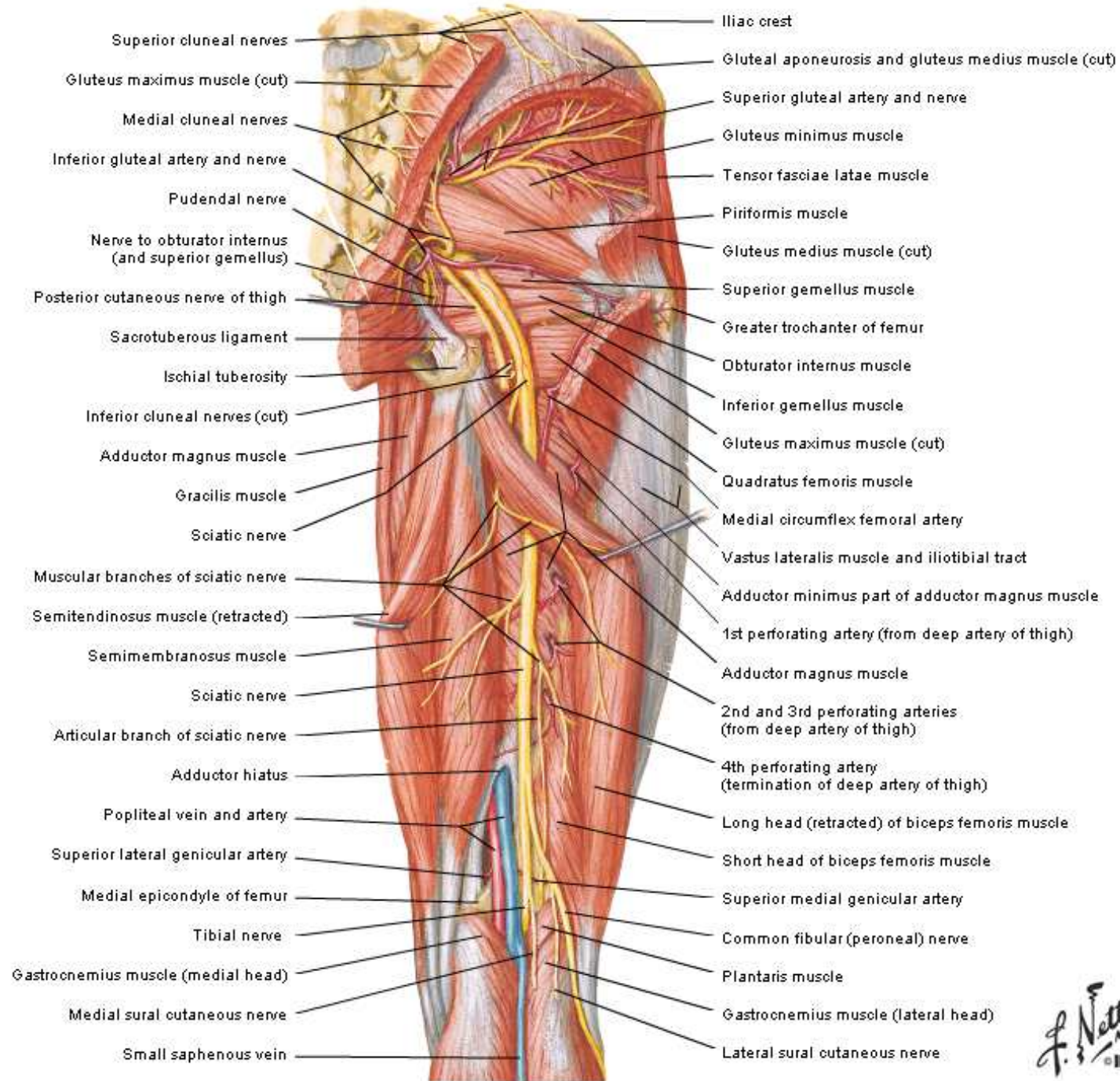


# Vascularizzazione arteriosa dell'arto inferiore





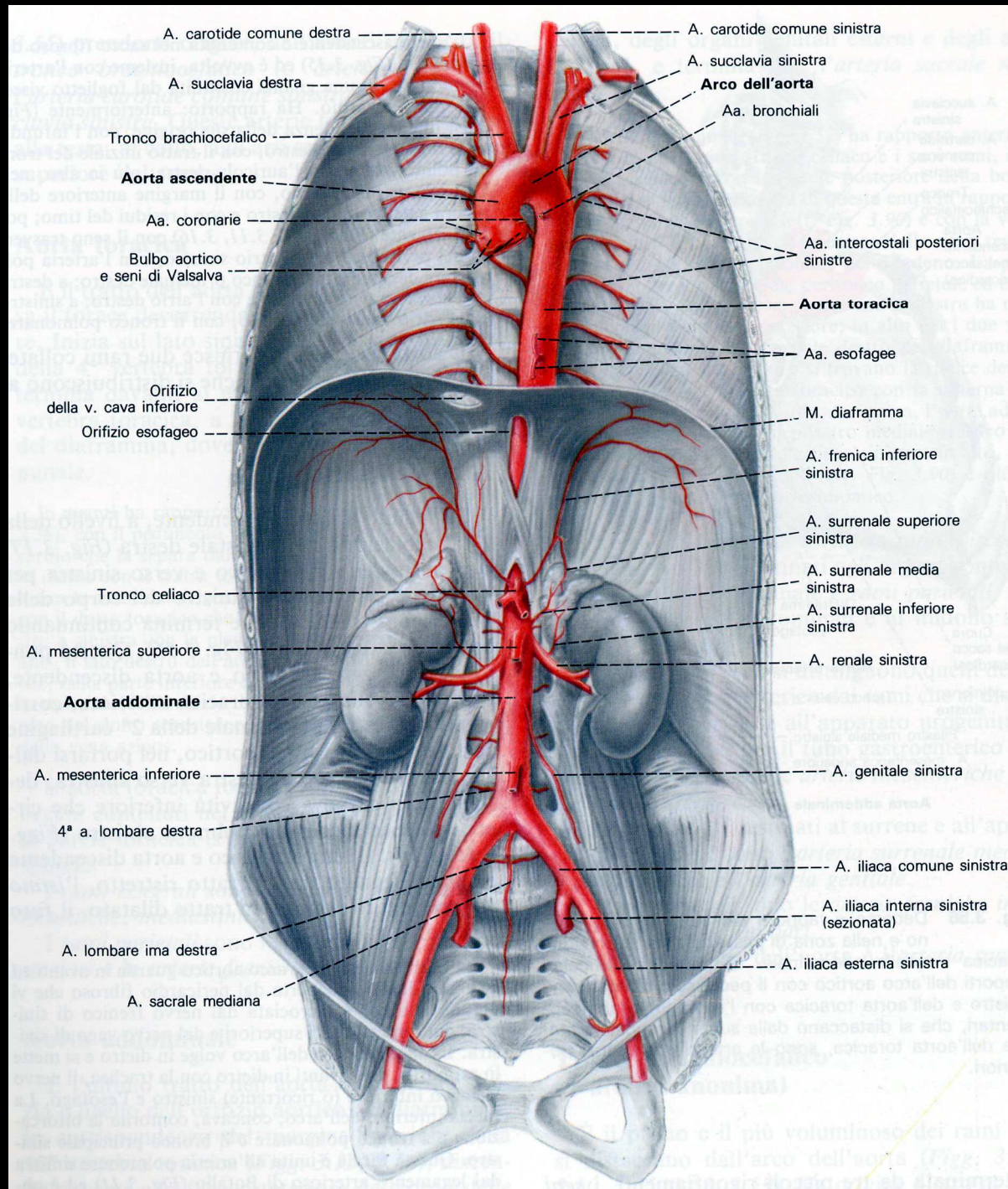


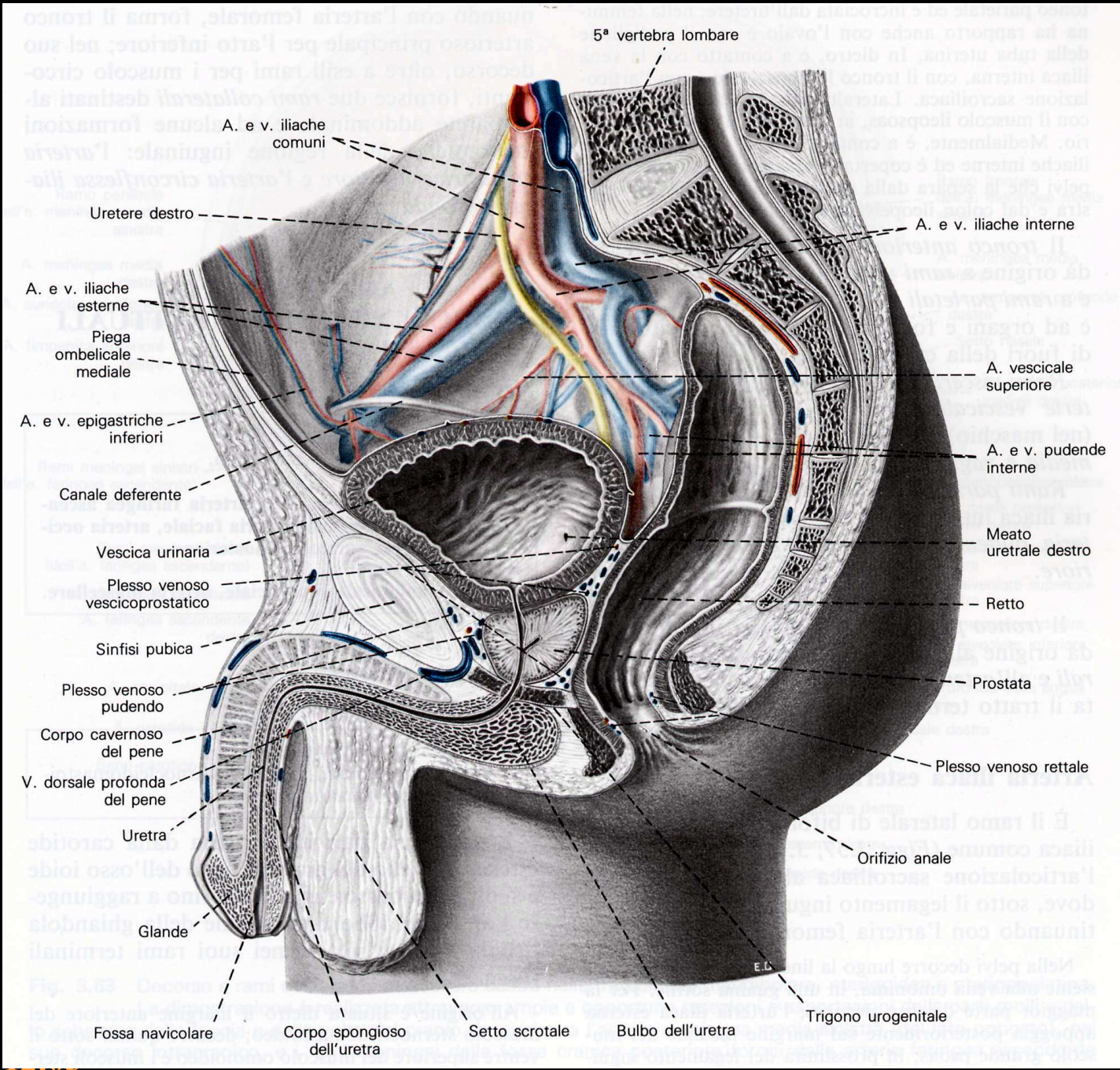


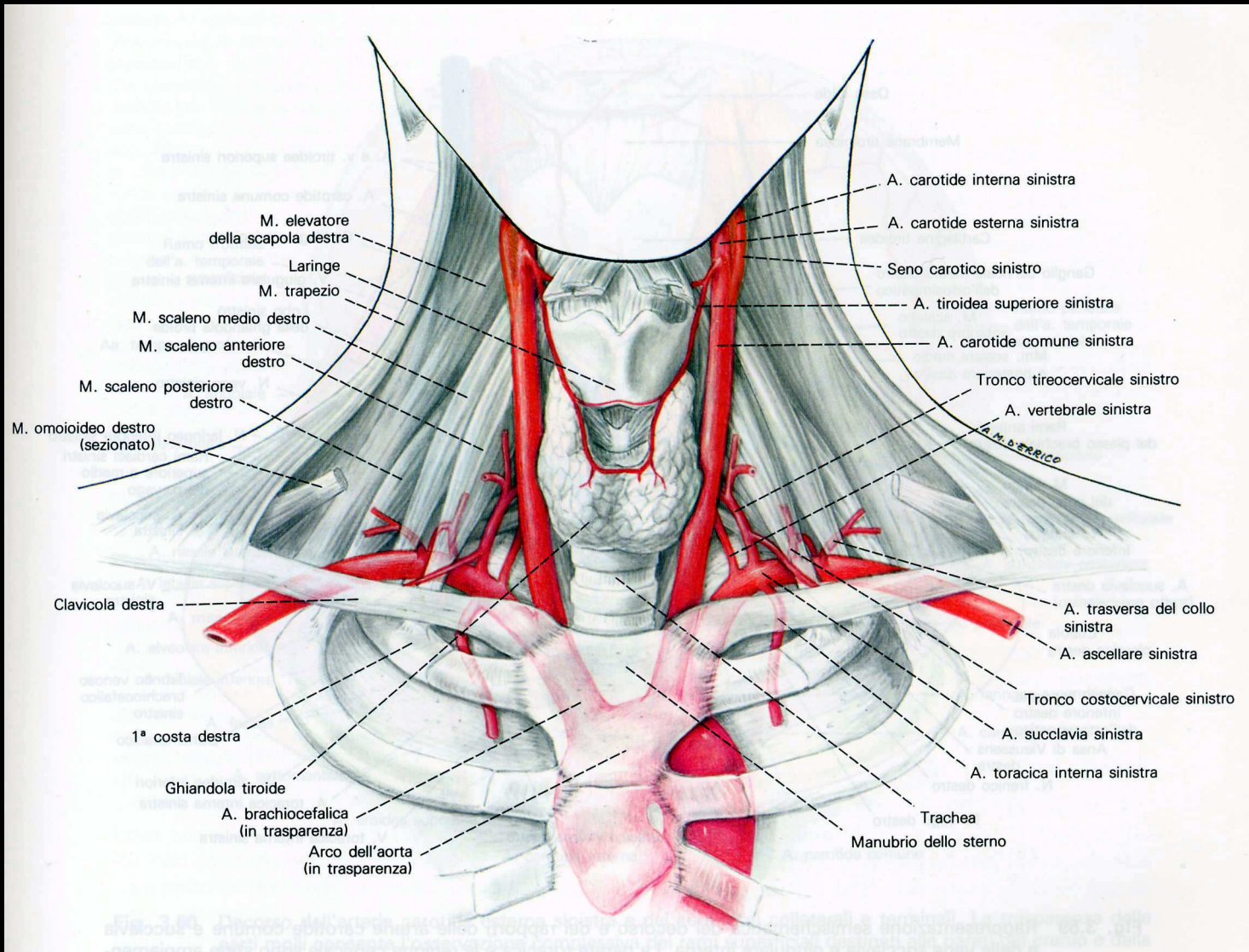
*F. Netter M.D.*  
© 1987

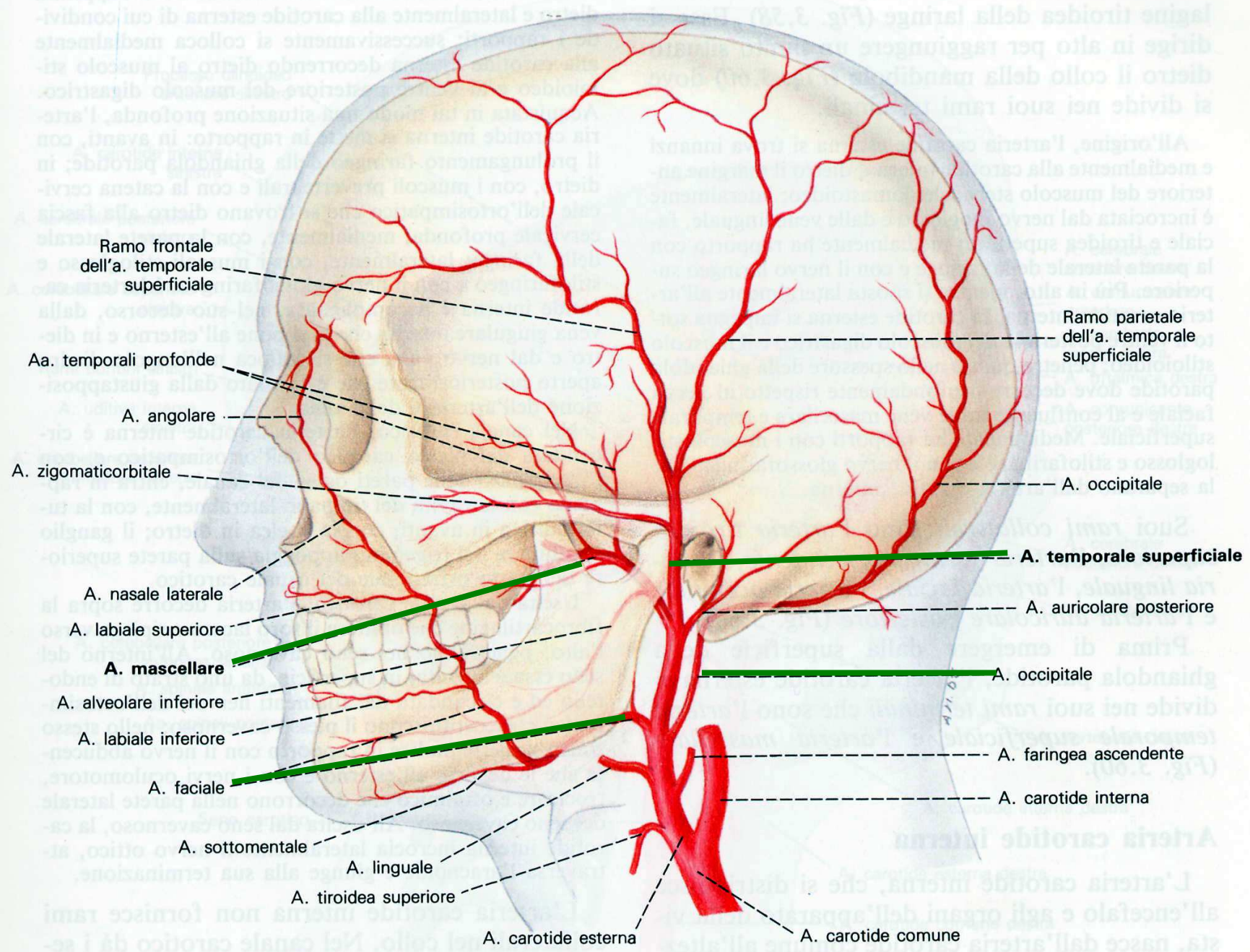


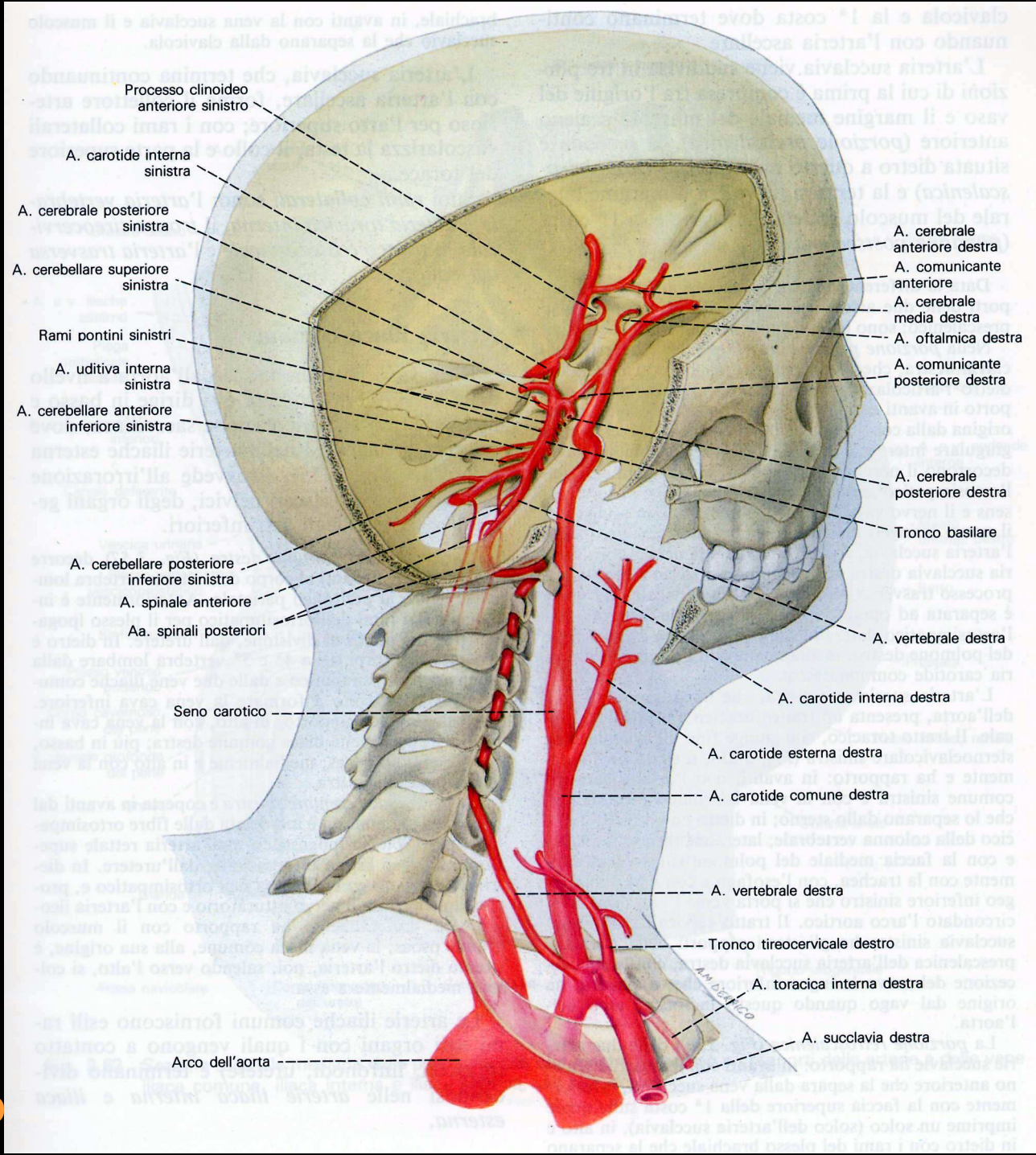
# Arteria AORTA

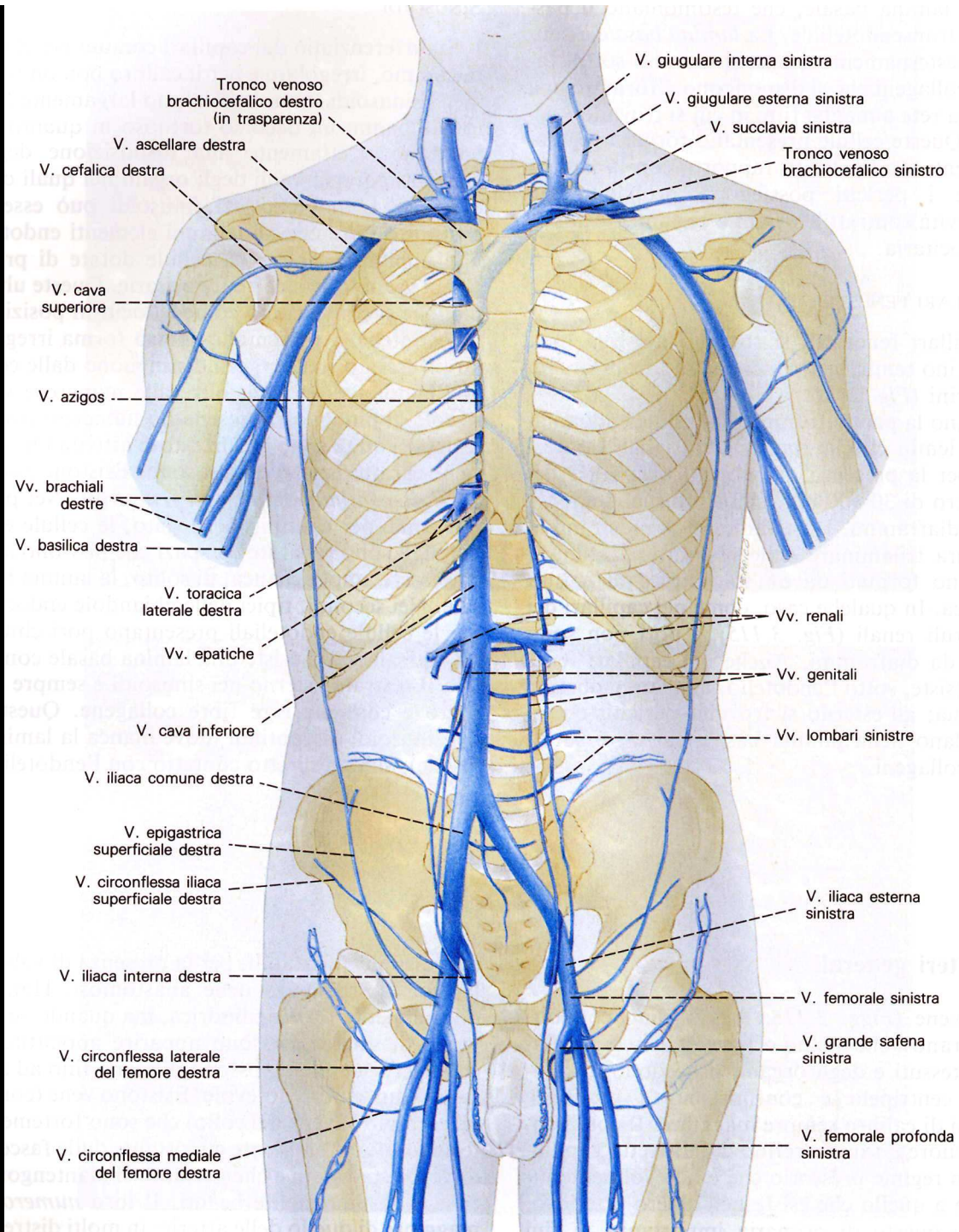


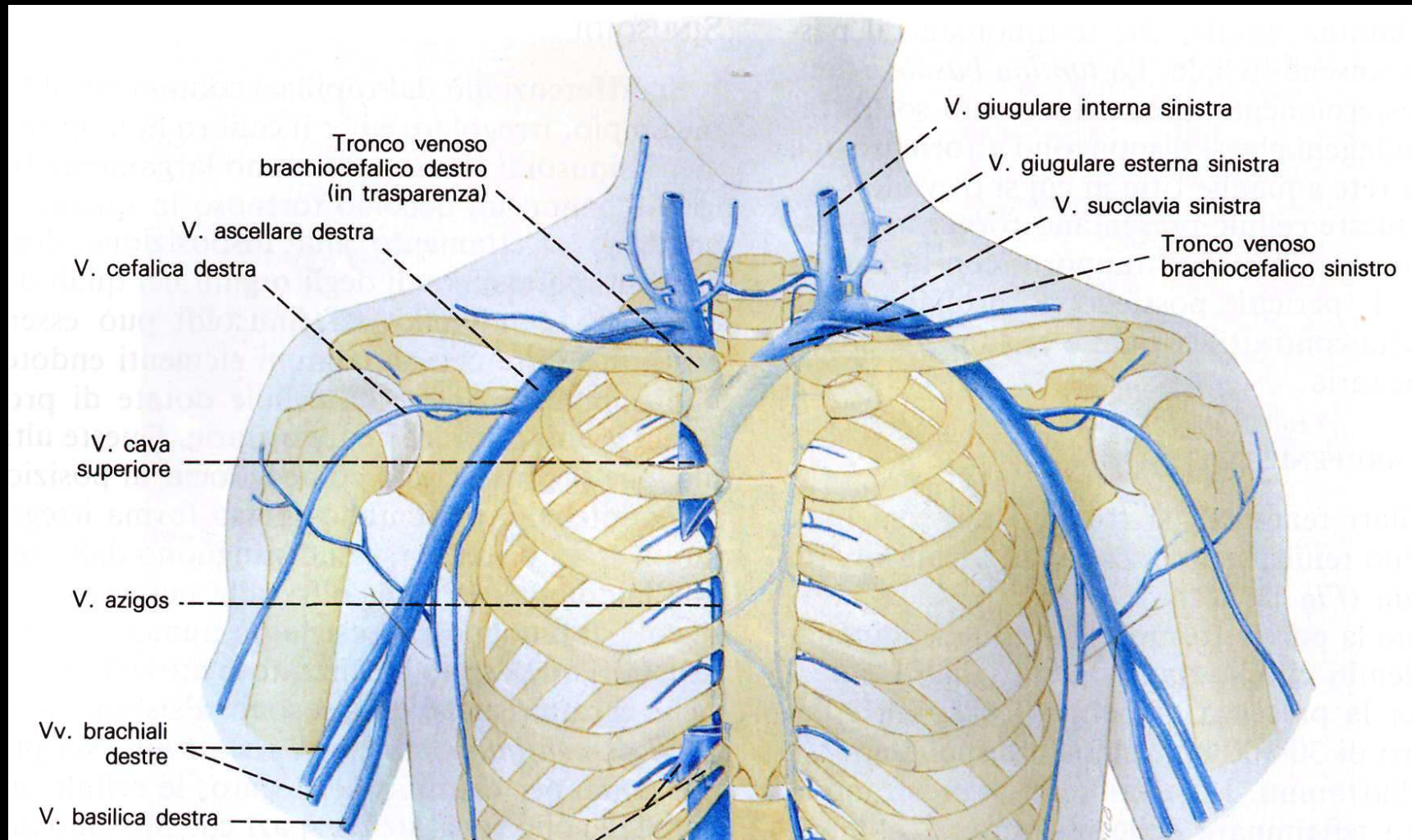


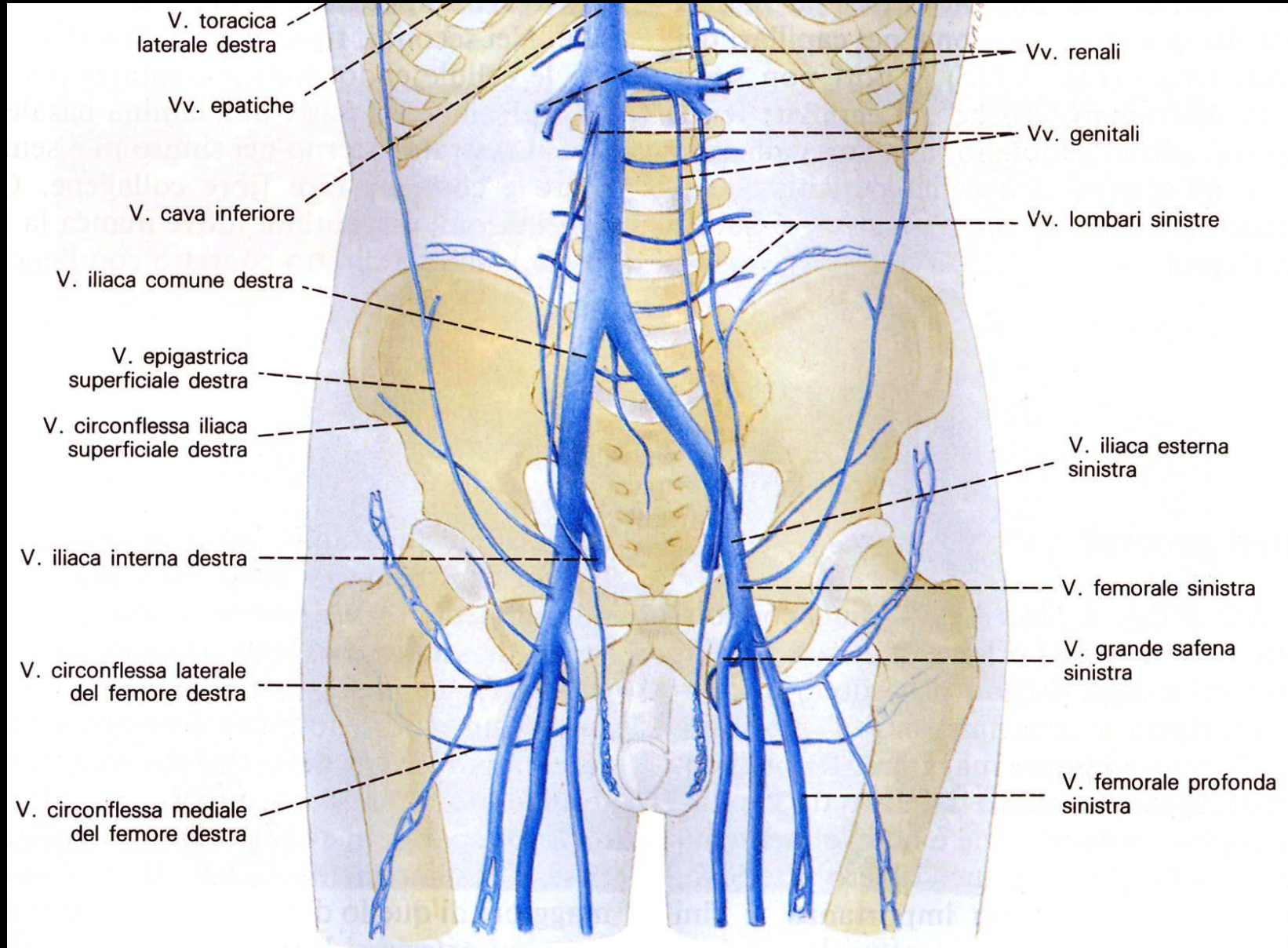






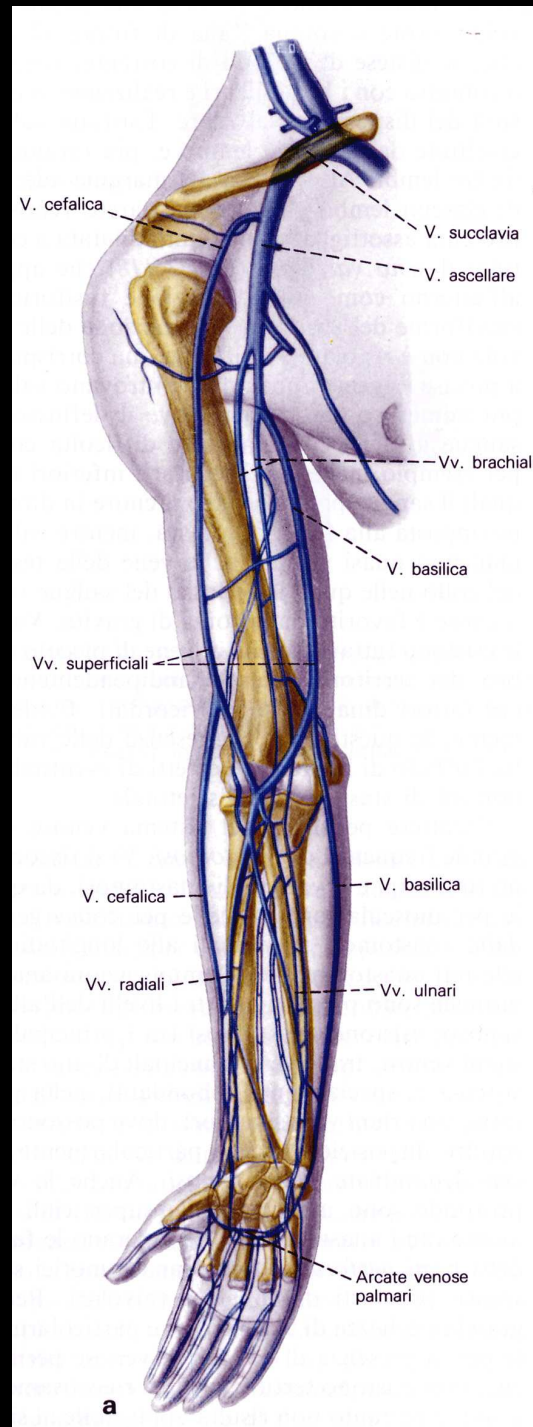




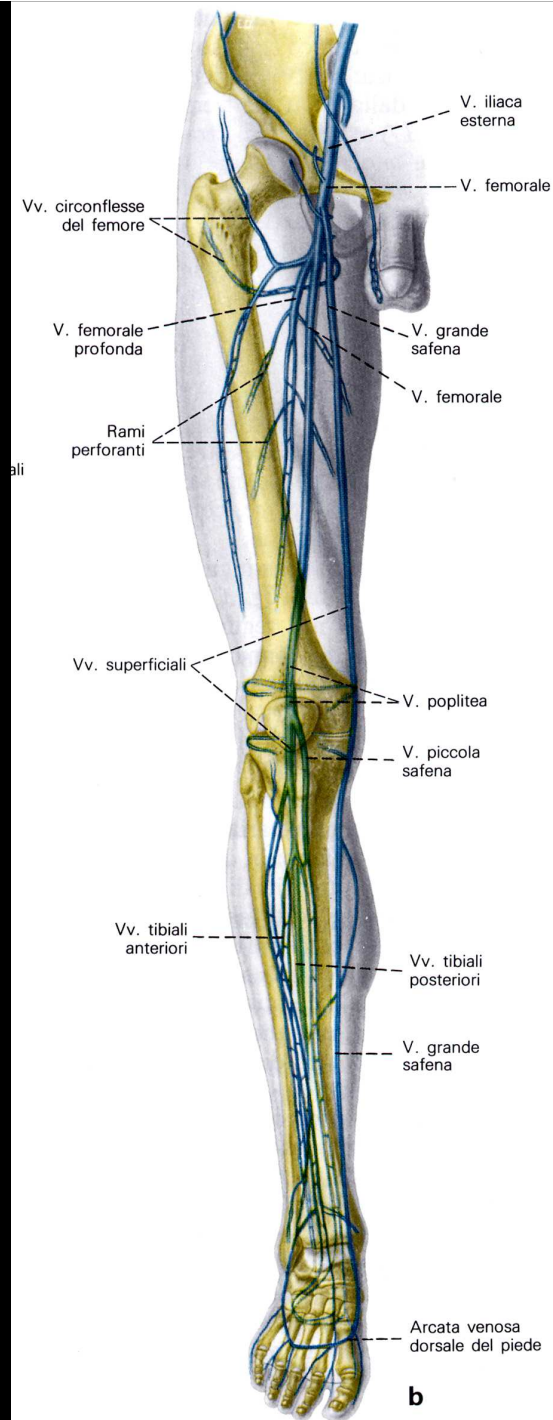


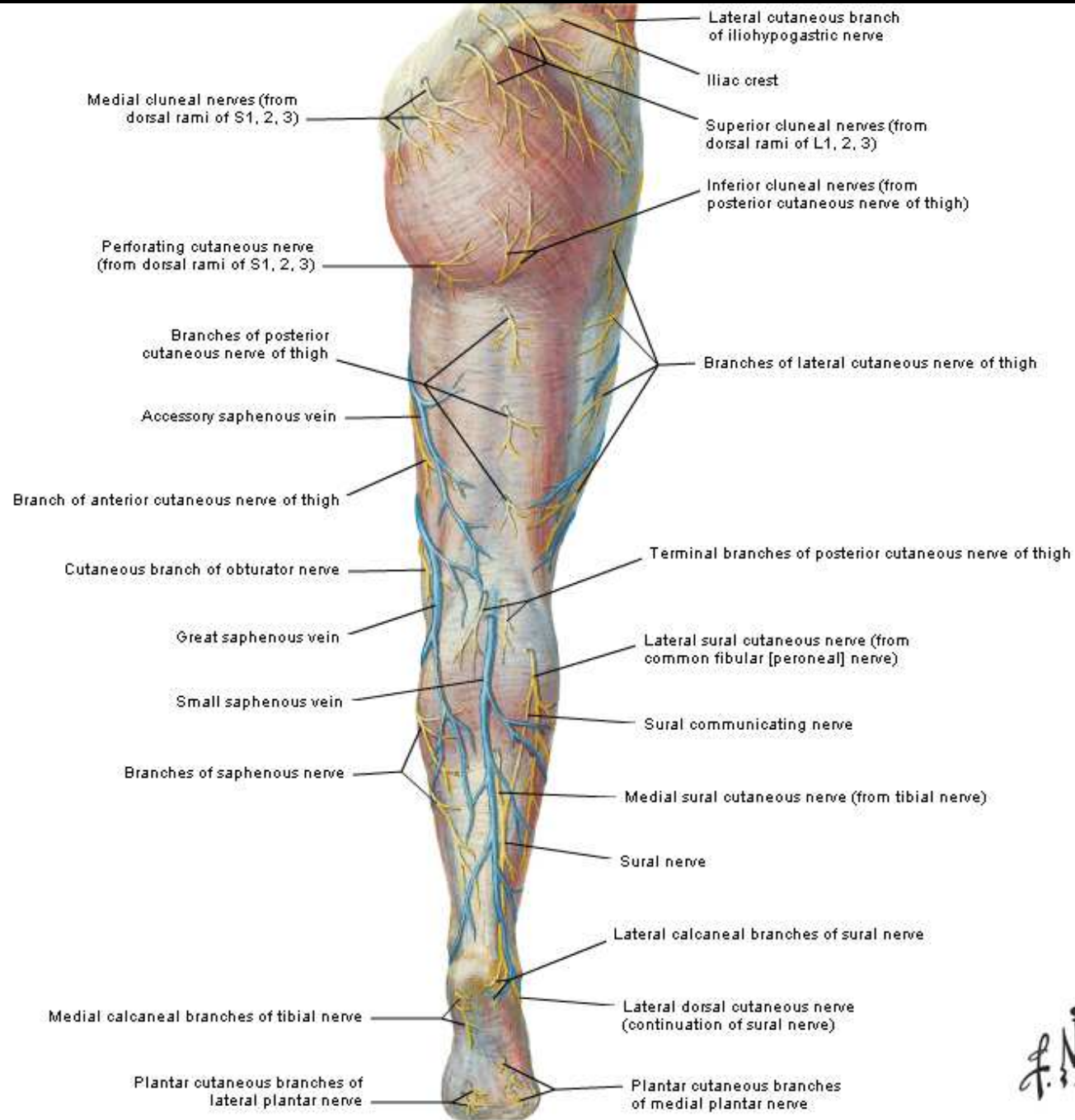


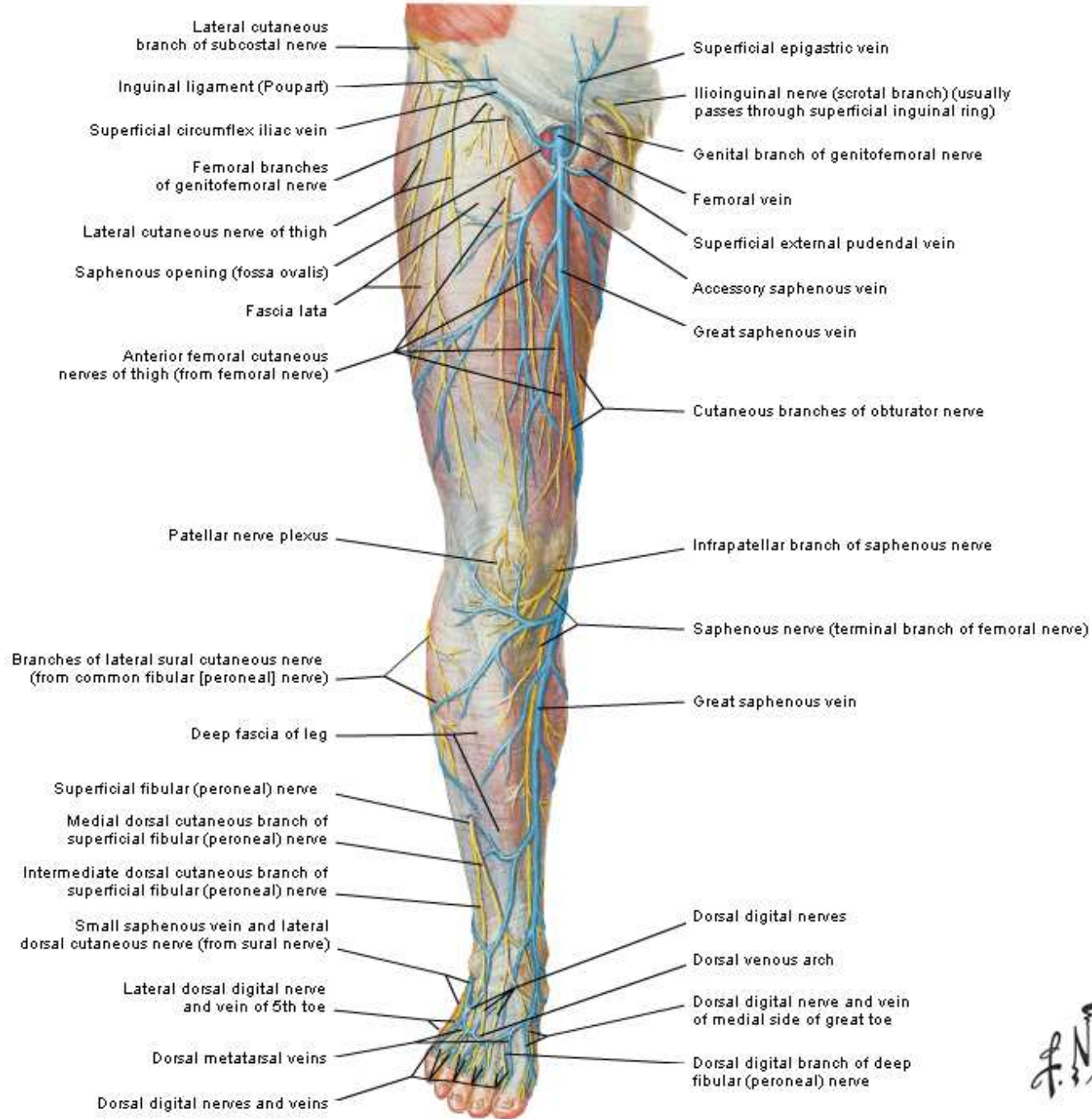
# Vascolarizzazione venosa dell'arto superiore



# Vascolarizzazione venosa dell'arto inferiore







*F. Netter M.D.*

